

References

1. Heinemann MH. Characteristics of cytomegalovirus retinitis in patients with acquired immunodeficiency syndrome. *Am J Med.* 1992;92:12S–16S.
2. Bloom JN, Palestine AG. The diagnosis of cytomegalovirus retinitis. *Ann Int Med.* 1998;109:963–969.
3. Ugen KE, McCallus DE, Von Feldt JM, Williams WV, Greene MI, Weiner DB. Ocular tissue involvement in HIV infection: Immunological and pathological aspects. *Immunol Res.* 1992;11:141–153.
4. Pepose JS, Holland GN, Nestor MS, Cochran AJ, Foos RY. Acquired immune deficiency syndrome: Pathogenic mechanism of ocular disease. *Ophthalmology.* 1985;92:472–484.
5. Bale JF Jr, O'Neil ME, Lyon B, Perlman S. The pathogenesis of murine cytomegalovirus ocular infection: Anterior chamber inoculation. *Invest Ophthalmol Vis Sci.* 1990;31:1575–1581.
6. Atherton SS, Newell CK, Kanter MY, Cousins SW. T cell depletion increases susceptibility to murine cytomegalovirus retinitis. *Invest Ophthalmol Vis Sci.* 1992;33:3353–3360.
7. Manning WC, Mocarski ES. Insertional mutagenesis of the murine cytomegalovirus genome: One prominent alpha gene (ie2) is dispensable for growth. *Virology.* 1988;167:477–484.
8. Atherton SS, Newell CK, Kanter MY, Cousins SW. Retinitis in euthymic mice following inoculation of murine cytomegalovirus (MCMV) via the supraciliary route. *Curr Eye Res.* 1991;10:667–677.
9. Sanes JR, Rubenstein JL, Nicolas JF. Use of a recombinant retrovirus to study post-implantation cell lineage in mouse embryos. *EMBO J.* 1986;5:3133–3142.
10. Bale JF Jr, O'Neil ME, Hogan RN, Kern ER. Experimental murine cytomegalovirus infection of ocular structures. *Arch Ophthalmol.* 1984;102:1214–1219.
11. Mocarski ES Jr, Abenes GB, Manning WC, Sambucetti LC, Cherrington JM. Molecular genetic analysis of cytomegalovirus gene regulation in growth, persistence and latency. *Curr Topics Microbiol Immunol.* 1990;154:47–74.

In Vivo Measurement of Lipofuscin in Stargardt's Disease—*Fundus flavimaculatus*

François C. Delori,*† Giovanni Staurenghi,*‡ Oliver Arend,*§ C. Kathleen Dorey,*† Douglas G. Goger,* and John J. Weiter*†

Purpose. Several histopathologic studies have concluded that Stargardt's disease (*Fundus flavimaculatus*) is associated with abnormally high levels of lipofuscin-like material in the retinal pigment epithelium. The purpose of this study was to determine whether this material has the same fluorescence characteristics as lipofuscin in vivo and whether noninvasive measurements identify a significant elevation in this material.

Methods. Five patients with autosomal recessive Stargardt's disease were included in this study, as were 45 healthy controls. All patients had the angiographic dark choroid sign. The intensity and emission spectra of lipo-

fuscin fluorescence were measured by noninvasive fundus spectrophotometry at 7° temporal to the fovea.

Results. The fluorescence intensities in the five patients with Stargardt's disease were significantly higher ($P < 0.0001$) than those observed in normal subjects of the same age. The emission spectra in the patients are similar in shape to those measured in normals, but flecks appear to shift the spectra toward shorter wavelengths.

Conclusions. The spectral characteristics of the fluorophore observed in patients with Stargardt's disease are consistent with those of retinal pigment epithelial lipofuscin. These patients have abnormally high levels of lipofuscin, confirming previous histopathologic observations. Noninvasive retinal pigment epithelial lipofuscin measurements may be a useful adjunct in the diagnosis of Stargardt's disease—*F. flavimaculatus*. *Invest Ophthalmol Vis Sci.* 1995;36:2327–2331.

Stargardt's disease (juvenile macular degeneration) is a hereditary macular degeneration characterized by diminished central visual acuity in the first several decades of life, the appearance of small yellowish lesions or flecks at the level of the retinal pigment epithelium (RPE) at the posterior pole, and atrophic changes in the macula. Fluorescein angiography often shows pronounced hypofluorescence of the choroid (dark choroid). Early in the disease, electrophysiology, night vision, and color vision are relatively normal. *Fundus flavimaculatus* is similar to Stargardt's disease except that the disease has a more progressive course and is diagnosed later in life (the macula is initially spared).

From the *Schepens Eye Research Institute, Harvard Medical School, the †Department of Ophthalmology, Harvard Medical School, Boston, Massachusetts; ‡University Eye Clinic, Institute of Biomedical Science, San Paolo Hospital, Milan, Italy; and §Augenlinik der Medizinische Fakultät der RWTH Aachen, Germany. Presented in part at the annual meeting of the Association for Research in Vision and Ophthalmology, Sarasota, Florida, 1993.

Supported by National Institutes of Health grant EYO-RO1-8511 (FCD, JJW) and in part by Deutsche Forschungsgemeinschaft Ar 197/4-1 (OA). Submitted for publication March 3, 1995; revised May 26, 1995; accepted June 8, 1995.

Proprietary interest category: N.

Reprint requests: François C. Delori, Schepens Eye Research Institute, 20 Staniford Street, Boston, MA, 02114.

Clinical and genetic aspects of Stargardt's disease and *F. flavimaculatus* were summarized recently by Weleber.¹ Most authors now agree that both entities are part of the same disease spectrum, and recent genetic analyses suggest that the two conditions are allelic disorders or result from mutations of distinct genes on chromosome 1p13.² In this report, we will refer to both conditions as Stargardt's disease (or Stargardt's). Although this disease is typically inherited as an autosomal recessive trait, there are reports of families with similar clinical features inherited as an autosomal dominant trait. Genetic linkage studies promise a greater understanding of the causes of Stargardt's disease and other retinal dystrophies.

Histopathologic examination of eyes with Stargardt's disease demonstrated large RPE cells densely packed with fluorescent granules that exhibited the ultrastructural and histochemical (periodic acid-Schiff positive) characteristics of lipofuscin.³⁻⁷ The possibility that the genetic lesion results in formation of abnormal lipofuscin was suggested,⁴ but this abnormality was never evaluated. Most histopathologic studies concluded that the lipofuscin content was greater than normal; however, the fluorescence spectrum was never compared to that of normal lipofuscin, and the quantity of lipofuscin was never measured. The purpose of this study was to compare by noninvasive measurements^{8,9} the emission spectra of the material accumulating in patients with Stargardt's disease with the spectra of lipofuscin formed in normal subjects and to determine whether noninvasive measurements identify significant increases of the fluorescence in these patients.

METHODS. Subjects. Five patients with Stargardt's disease were included in this study (Table 1). None of the patients had a family history of this disease except for patient 2, who had an affected sibling diagnosed at 12 years of age. This is consistent with autosomal recessive inheritance in all study patients. Ophthalmoscopic examination revealed atrophic changes in the maculae and yellowish flecks throughout the

posterior pole of patients 1, 3, and 5. Patient 2 had only early atrophic changes and flecks in the macula, and patient 4 had flecks but no atrophy in the macula (*F. flavimaculatus*). Fluorescein angiography demonstrated a dark choroid in all five patients. Goldman perimetry showed normal peripheral isopters and a central scotoma in patients 1, 3, and 5.

Forty-five healthy subjects ranging in age from 15 to 67 years (20 females, 25 males) served as controls.⁹ All subjects were white, had no fundus disease, and had no or minimal nuclear sclerosis. This study followed the tenets of the Declaration of Helsinki and was approved by the SERI Human Study Committee. Informed consent was obtained from all patients and control subjects before participation in the study.

Fluorescence Measurements. We used the fundus spectrophotometer⁸ to measure the intrinsic fundus fluorescence at 7° temporal to the fovea in both eyes of all patients (except for patient 5) and in one eye for all normal controls. Fluorescence was excited at 510 nm (full width at half maximum: 20 nm) and the emission spectra were measured between 520 and 800 nm (spectral resolution: 6 nm). Excitation at 510 nm generally provides maximal excitation in vivo.⁹ The diameter of the sampling field was 585 μ (2° visual angle). In patient 4, a smaller sampling field of 380 μ (1.3°) also was used to investigate the fluorescence of flecks using excitations at 470 and 510 nm.

The pupils were dilated to a diameter of at least 6.1 mm with 1% tropicamide. The instrument was aligned to the pupil under infrared illumination, and the site of interest was selected while viewing the fundus and directing the subject's gaze with an internal fixation target (for the eye tested). Confocal focus was achieved by aligning images of the illumination and the sampling fields on the subject's fundus. Each fluorescence spectrum measurement was followed by a baseline spectrum measurement to account for contributions of crystalline lens fluorescence, stray light in the instrument, and dark-leakage current from the detector. Light levels used for acquisition of one spectrum were 2% to 4% of the maximum permissible exposure.⁸

TABLE 1. Patient Characteristics

Patient	Age (years)	Sex	Diagnosis	VA/OS	VA/OD	Age at Diagnosis	Flecks
1	12	M	ST	20/300	20/300	10	++
2	22	M	ST	20/25	20/20	22	0
3	25	F	ST	20/200	20/200	19	+++
4	50	F	FF	20/25	20/25	42	+
5	59	F	ST	20/160	20/200	29	++

The number of flecks at the measurement site (7° temporal to the fovea) was ranked from none (0) to many (+++). ST = Stargardt's disease; FF = fundus flavimaculatus; VA = best-corrected visual acuity; OS = left eye; OD = right eye.

Two successive measurements of fluorescence were made, and the results were averaged. All data were corrected for the difference in excitation energy, for sampling area, and for the spectral sensitivity of the detecting system. In this study, no corrections were used to account for absorption by the ocular media. Fundus fluorescence is expressed in ($\text{nJ} \cdot \text{nm}^{-1} \cdot \text{sr}^{-1}$) of emitted fluorescence per J of excitation energy.^{8,9}

RESULTS. Fluorescence spectra obtained in all patients with Stargardt's are presented in Figure 1, with representative spectra from normal subjects in the same age ranges. Comparison of fluorescence intensities is best seen in Figure 2, in which the fluorescence at 620 nm is displayed as a function of age for both eyes of the five patients (only the left eye in patient 5) and for the healthy reference population ($n = 45$).

Because fundus fluorescence in normal subjects increases significantly with age, it is necessary to com-

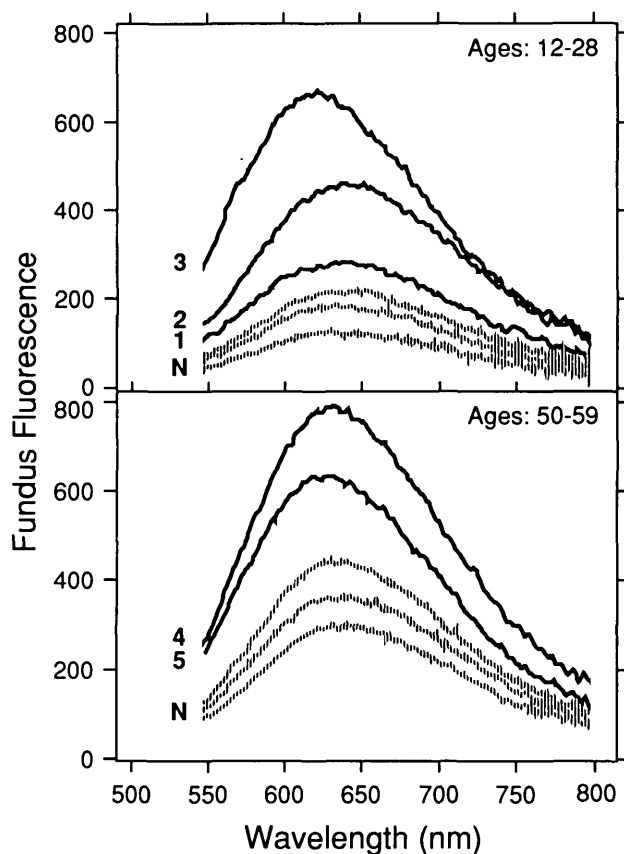


FIGURE 1. Fluorescence spectra (excitation: 510 nm) for the left eyes of all patients with Stargardt's disease (thick lines = patient numbers) and representative spectra of normal subjects in the same age ranges (interrupted lines = N). All spectra were measured at 7° temporal to the fovea (sampling field: 2° diameter). Fundus fluorescence is expressed in ($\text{nJ} \cdot \text{nm}^{-1} \cdot \text{sr}^{-1}$) per J.

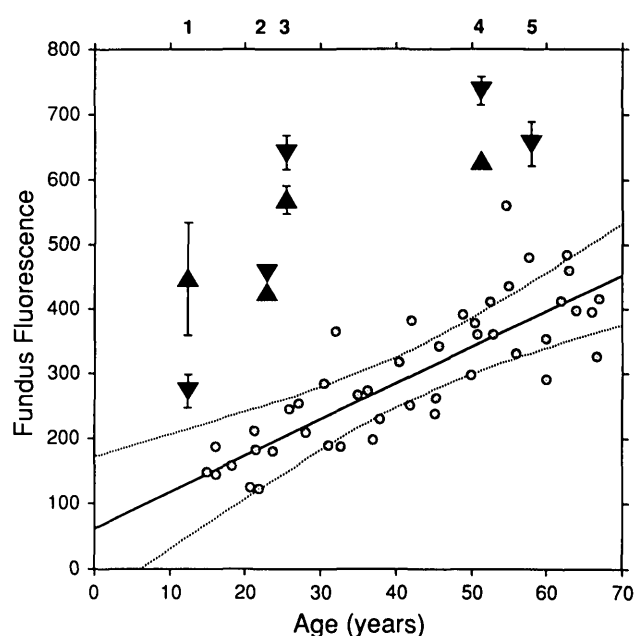


FIGURE 2. Fundus fluorescence (excitation: 510 nm; emission: 620 nm) for patients with Stargardt's disease (triangles) and for healthy controls (circles; $n = 45$). Results for measurements in both eyes (▲ = right eye; ▼ = left eye) of patients are presented (except for the oldest patient, in whom only the left eye was tested). The error bars represent ± 1 SD. The age-related increase in lipofuscin in 45 normal subjects is represented in a solid regression line ($r^2 = 0.68$; $P < 0.0001$) and 99.99% confidence intervals (dotted lines). Fluorescence intensities were averaged in a 20-nm band centered at 620 nm and are expressed in ($\text{nJ} \cdot \text{nm}^{-1} \cdot \text{sr}^{-1}$) per J.

pare the fluorescence in patients with the data of normals at the same age (Fig. 2). The fluorescence at 620 nm for all patients with Stargardt's is higher than the 99.99% confidence interval derived from the regression on the normal data, indicating highly significant increases in fluorescence in these patients ($P < 0.0001$). For patients 1 to 5, respectively, the mean fluorescence for both eyes was 2.7 ± 0.9 , 2.4 ± 0.0 , 3.0 ± 0.2 , 1.9 ± 0.2 , and 1.7 (one eye) times higher than the mean normal level at the same age. Thus, fundus fluorescence in the patients with Stargardt's disease is considerably higher than that in the normal subjects.

None of the patients had advanced atrophy at the 7° temporal measurement site. Those with central atrophy (patients 1, 3, and 5) had poor fixation. The variability in fluorescence measurements in these patients reflects the movement of the measurement site, even though it was aligned under fundus observation. Fluorescence in atrophy was substantially below the normal levels in intensity, and the spectra were distorted, showing the absorption band of hemoglobin

superimposed on the collagen–elastin fluorescence from the choroid and sclera.

Spectral characteristics of fundus fluorescence in patients with Stargardt's were similar to those of normal subjects (Fig. 1), albeit shifted toward shorter wavelengths in some patients. The short wavelength shift appears to be related to the density of flecks at the site of measurement (Table 1). The largest shift was observed in patient 3, who also ranked highest for density of flecks. This possibility was supported by observations in patient 4, whose good fixation allowed more focal measurements on and off flecks with a smaller sampling field (Fig. 3). The emission spectra on flecks are shifted by 10 and 15 nm (excitation: 510 and 470 nm, respectively) toward shorter wavelengths compared to those from a neighboring site without flecks. These shifts are pronounced considering that maximal wavelengths in normals show little variability (maximal wavelength: 631 ± 4 nm and 612 ± 6 nm, at excitations of 510 and 470 nm, respectively).⁹ Fluorescence intensities measured on and off flecks do not appear to be substantially different from each other. Both fluorescences, measured at 4° from the fovea, are smaller than those obtained at 7° from the fovea; this reflects the normal profile of fundus fluorescence at the posterior pole.⁹

DISCUSSION. Lipofuscin normally accumulates in the RPE as a function of age and may be further increased in disease of the photoreceptors and RPE.¹⁰ To date, lipofuscin measurements have been limited

to autopsy eyes.^{10–12} Recently, a spectrofluorometric technique has been developed to measure RPE lipofuscin *in vivo*.⁸ We have shown in studies on normal subjects that the age-related, topographic, and spectral characteristics of fundus fluorescence are consistent with lipofuscin.⁹

The current study demonstrates significantly increased lipofuscin in patients with autosomal recessive Stargardt's disease (Figs. 1, 2). Our patients all showed the dark choroid sign in fluorescein angiography. In this well-defined group of patients with Stargardt's disease, we have quantitatively confirmed earlier histologic observation of increased RPE lipofuscin.

In patients with Stargardt's, fundus fluorescence emission spectra, outside areas with abundant flecks, are similar to those of normal subjects. Lipofuscin has been shown to be a mixture of at least 10 fluorophores, three of which—the “orange-red” emitters—have excitation spectra that extend substantially above 400 nm and emission maxima at 620 to 630 nm.¹³ We have demonstrated that the emission spectra obtained *in vivo* with 510 nm excitation correspond essentially with these orange-red lipofuscin fluorophores.⁹ Eldred and Lasky¹⁴ identified the structure of one of these orange-red fluorophores (fluorophore VIII¹³) as an adduct of retinaldehyde and ethanolamine and suggested that its formation may be enhanced if the activity of retinol dehydrogenase is depressed. Birnbach et al³ further proposed that retinol dehydrogenase may be defective in Stargardt's disease. The observed increase in the 620 nm fluorescence is consistent with such a hypothesis, but, without knowledge of the behavior of the shorter wavelength fluorophores in Stargardt's disease, our data can neither confirm nor refute this hypothesis.

The spectral shift toward shorter wavelengths (Fig. 3) observed in some patients appears to be related to the number of flecks at the measurement site. Whether this shift is caused by anatomic changes in the optical pathway, such as increased intracellular or extracellular material (light absorption and scattering), by a change in composition of RPE lipofuscin,¹³ or by the addition of other unknown fluorophores, cannot be resolved on the basis of our preliminary study. Because our observations in one subject indicate that the intensity of fluorescence on the flecks was not higher than in the surrounding areas, it is unlikely that the lipofuscin content at the flecks was higher in that individual.

It has been suggested that the dark choroid sign in fluorescein angiography could be the result of increased lipofuscin.¹⁵ Our data cannot prove this because no patients with Stargardt's without a dark choroid were included in our study. However, increased lipofuscin *by itself* is not likely to account for the dark

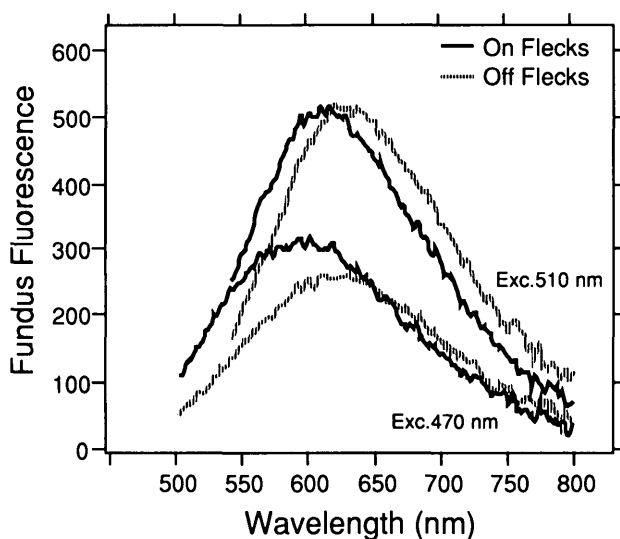


FIGURE 3. Fluorescence spectra (excitation: 470 and 510 nm) obtained on and off flecks in patient 4. The spectra were measured at approximately 4° inferonasal to the fovea (sampling field: 1.3° diameter). Fundus fluorescence is expressed in ($\text{nj} \cdot \text{nm}^{-1} \cdot \text{sr}^{-1}$) per J.

choroid sign because comparable levels of lipofuscin are found in older normals who do not have a dark choroid in fluorescein angiography. Patients 1 and 2 have levels equivalent to those found in 50- to 60-year-old normals (Fig. 2). In fact, fluorescence in older subjects is higher than shown in Figure 2 because the data presented here have not been corrected for absorption by the ocular media, which increases with increasing age. Other explanations for the dark choroid may involve changes in the size and distribution of the lipofuscin and/or melanin granules or the build-up of extracellular materials.³⁻⁷

The diagnosis of Stargardt's disease may be difficult because of the wide spectrum of clinical findings as well as the variable inheritance implying a heterogeneous disease. The objective and quantitative measurement of RPE lipofuscin may be a useful adjunct to the diagnosis in certain patients with Stargardt's disease. Furthermore, the spectral information provided by this technique may be useful in interpreting the nature of the flecks and in explaining the dark choroid.

In summary, the spectral characteristics of the fluorescence detected in patients with Stargardt's are consistent with those of lipofuscin accumulating in the aging RPE. The significant increase of lipofuscin levels observed in these patients confirms previous histopathologic reports. In future studies, we will examine a larger number of patients with Stargardt's disease and include those with autosomal dominant inheritance and those without a dark choroid.

Key Words

Fundus flavimaculatus, lipofuscin, spectrophotometry, Stargardt's disease

References

1. Weleber RG. Stargardt's macular dystrophy. *Arch Ophthalmol*. 1994;112:752-753.
2. Gerber S, Rozet J, Bonneau D, et al. A gene for late-onset fundus flavimaculatus with macular dystrophy maps to chromosome 1p13. *Am J Hum Genet*. 1995;56:396-399.
3. Birnback CD, Jarvelainen M, Possin DE, Milam AH. Histopathology and immunocytochemistry of the neurosensory retina in fundus flavimaculatus. *Ophthalmology*. 1994;101:1211-1219.
4. Eagle RC, Lucier AC, Bernadino VB, Janoff M. Retinal pigment epithelial abnormalities in fundus flavimaculatus: A light and electron microscopic study. *Ophthalmology*. 1980;87:1189-1200.
5. Lopez PF, Maumenee IH, de la Cruz Z, Green WR. Autosomal-dominant fundus flavimaculatus: Clinicopathologic correlation. *Ophthalmology*. 1990;97:798-809.
6. McDonnell PJ, Kivlin JD, Maumenee IH, Green WR. Fundus flavimaculatus without maculopathy: A clinicopathologic study. *Ophthalmology*. 1986;93:116-119.
7. Steinmetz RL, Garner A, Maguire JJ, Bird AC. Histopathology of incipient fundus flavimaculatus. *Ophthalmology*. 1991;98:953-956.
8. Delori FC. Spectrophotometer for noninvasive measurement of intrinsic fluorescence and reflectance of the ocular fundus. *Appl Optics*. 1994;33:7439-7452.
9. Delori FC, Dorey CK, Staurenghi G, Arend O, Goger DG, Weiter JJ. In vivo fluorescence of the ocular fundus exhibits retinal pigment epithelium lipofuscin characteristics. *Invest Ophthalmol Vis Sci*. 1995;36:718-729.
10. Dorey CK, Staurenghi G, Delori FC. Lipofuscin in aged and AMD eyes. In: Holyfield JG et al, eds. *Retinal Regeneration*. New York: Plenum Press; 1993:3-14.
11. Feeney-Burns L, Hilderbrand ES, Eldridge S. Aging human RPE: Morphometric analysis of macular, equatorial, and peripheral cells. *Invest Ophthalmol Vis Sci*. 1984;25:195-200.
12. Weiter JJ, Delori FC, Wing G, Fitch KA. Retinal pigment epithelial lipofuscin and melanin and choroidal melanin in human eyes. *Invest Ophthalmol Vis Sci*. 1986;27:145-152.
13. Eldred GE, Katz ML. Fluorophores of the human retinal pigment epithelium: Separation and spectral characterization. *Exp Eye Res*. 1988;47:71-86.
14. Eldred CE, Laskey MR. Retinal age pigments generated by self-absorbing lysosomotropic detergents. *Nature*. 1993;361:724-726.
15. Fish G, Grey R, Sehmi KS, Bird AC. The dark choroid in posterior retinal dystrophies. *Br J Ophthalmol*. 1981;65:359-363.