

# Retinal Blood Flow Changes in Type I Diabetes

## A Long-Term, Follow-Up Study

Suguru Konno,\*† Gilbert T. Feke,\* Akitoshi Yoshida,† Naoki Fujio,\*†  
Douglas G. Goger,\* and Sheldon M. Buzney\*

**Purpose.** The authors previously reported that blood speeds in the retinal arteries were significantly lower in patients with type I diabetes than in controls without diabetes. The purpose of this long-term, follow-up study was to characterize the natural course of changes in blood speed and blood flow in these patients.

**Methods.** Twenty-four patients were followed up with serial annual measurements of the blood flow in a temporal retinal artery using the bidirectional laser Doppler technique and monochromatic photography. The follow-up period ranged from 2 to 6 years (mean, 3.8 years). Using standardized color fundus photography and fluorescein angiography, a retinopathy score was generated for each eye studied. Linear regression analysis was used to compute the slope of the change in retinal blood flow for each patient during the follow-up period.

**Results.** Retinal blood flow slopes were negative in 15 patients and positive in 9 patients. Multiple linear regression analysis showed that the retinal blood flow slopes were significantly related to the retinal blood flow measured at entry to the study and to the median duration of diabetes during the follow-up period ( $R^2 = 0.56$ ;  $P = 0.0002$ ). There was a positive correlation between the retinal blood flow slopes and the median retinopathy score during the follow-up period ( $P = 0.47$ ;  $P = 0.02$ ).

**Conclusions.** As duration of diabetes becomes longer and retinopathy becomes more severe, there is a transition from negative to positive retinal blood flow slopes. This bimodal relationship between the change in retinal blood flow and the duration of diabetes reflects the complex pathologic alterations that occur in the diabetic retina. Invest Ophthalmol Vis Sci. 1996;37:1140–1148.

Retinal circulatory alterations in diabetes are expected to occur during the course of the pathologic changes and blood rheologic changes. We have previously reported in a cross-sectional study<sup>1</sup> that blood speeds in the retinal arteries of patients with type I diabetes (insulin-dependent diabetes mellitus) are significantly lower than normal. Because arterial blood speeds were already low before the clinical appearance of retinopathy in the patients studied, retinal circulatory alterations appear to be sensitive indicators of

microvascular pathology. Our findings were consistent with the results reported by Arend et al,<sup>2</sup> who found abnormally reduced blood speeds in perifoveal capillaries in patients with diabetes, and they were consistent with the findings reported by Grunwald et al<sup>3</sup> in their initial report, in which they found abnormally low blood speeds in the major retinal veins of patients with type I diabetes. We also reported<sup>1</sup> that centerline blood speed decreases with increasing duration of diabetes between 7 and 20 years; however, there were large patient-to-patient differences in centerline blood speed. In a long-term, follow-up study, Rimmer et al<sup>4</sup> reported a progressive slowing of the blood speeds in the perifoveal capillaries over a time interval of several years in patients with background retinopathy. It is likely that a more sensitive way to detect subtle blood flow changes in diabetes is by means of longitudinal follow-up studies.

From the \*Schepens Eye Research Institute and Harvard Medical School, Boston, Massachusetts, and the †Department of Ophthalmology, Asahikawa Medical College, Asahikawa, Japan.

Supported in part by United States Public Health grant EY01303 (GTF). Submitted for publication May 8, 1995; revised January 25, 1996; accepted January 30, 1996.

Proprietary interest category: N.

Reprint requests: Gilbert T. Feke, Schepens Eye Research Institute, 20 Staniford Street, Boston, MA 02114.

In this long-term, follow-up study, we have sought to clarify the natural history of retinal circulatory abnormalities in patients with type I diabetes. The advantages inherent in a longitudinal study have allowed us to understand more clearly the complex behavior of retinal blood flow changes in these patients.

## METHODS

Subjects for the study were 24 patients with type I diabetes (13 males, 11 females), who were available for serial annual measurements of blood flow in a single major temporal retinal artery in one eye for at least 2 years. Twenty-one of 24 were patients who were included in our previous cross-sectional study.<sup>1</sup> Criteria for inclusion in the study were no known diseases other than type I diabetes, no ocular diseases other than retinopathy, no prior eye surgery or photocoagulation treatment, adequate pupillary dilatation, and clear ocular media. The follow-up period ranged from 2 to 6 years (mean, 3.8 years). Three patients were followed for 2 years, seven for 3 years, six for 4 years, seven for 5 years, and one for 6 years. On entering the study, their ages were  $25.3 \pm 1.2$  years (mean  $\pm$  SEM), and the age range was 19 to 39 years. Age at onset of diabetes was  $10 \pm 1.5$  years, and the range was 1 to 30 years. Duration of diabetes was  $15.3 \pm 1.2$  years, and the range was 7 to 32 years. The procedures performed in the study followed the tenets of the Declaration of Helsinki and were approved by the Schepens Eye Research Institute Human Studies Committee. Written, informed consent was obtained from all patients. At entry to the study, glycosylated hemoglobin, measured according to the method of Gabbay et al.,<sup>5</sup> was  $11.7\% \pm 0.4\%$  and ranged from 7.6% to 17.4% (upper limit of normal range, 6%); daily insulin dosage was  $54.7 \pm 4.2$  IU and ranged from 25 to 104 IU. At the final visit, glycosylated hemoglobin was  $11.6\% \pm 0.4\%$  and ranged from 8.7% to 16.1%; daily insulin dosage was  $54.4 \pm 3.9$  IU and ranged from 24 to 120 IU. During the follow-up period, glycosylated hemoglobin increased in eight patients and decreased in 16. The mean change was  $-0.18\% \pm 0.17\%$  per year. Daily insulin dosage increased in 11 patients and decreased in 13. The mean change was  $-0.05 \pm 0.81$  IU/year.

At each visit, intraocular pressure was measured by applanation tonometry, and brachial artery blood pressure was measured by sphygmomanometry. Finger capillary blood glucose was measured immediately before the laser Doppler measurements using a Glucoscan (Lifescan, Mountain View, CA) blood glucose monitor. On entering the study, intraocular pressure in the eye studied was  $17.4 \pm 0.6$  mm Hg, mean blood pressure  $85.4 \pm 1.4$  mm Hg, heart rate  $75.2 \pm 2.7$

beats/minute, and finger capillary blood glucose  $189.8 \pm 20$  mg/dl. At the final visit, intraocular pressure was  $15.6 \pm 0.7$  mm Hg, mean blood pressure  $85.5 \pm 1.9$  mm Hg, heart rate  $72 \pm 2.5$  beats/minute, and finger capillary blood glucose  $199.2 \pm 18.1$  mg/dl. During the follow-up period, intraocular pressure increased in two eyes studied and decreased in 22. The mean change was  $-0.63 \pm 0.14$  mm Hg per year. Mean blood pressure increased in 11 patients and decreased in 13. The mean change was  $0.05 \pm 0.61$  mm Hg per year. Heart rate increased in nine patients and decreased in 15. The mean change was  $-0.86 \pm 0.49$  beats/minute per year. Finger capillary blood glucose increased in 13 patients and decreased in 11. The mean change was  $12.6 \pm 8.4$  mg/dl per year.

Each patient underwent a complete ophthalmologic examination, which included standardized color fundus photography<sup>6</sup> and fluorescein angiography<sup>7</sup> at each visit. Photographs and angiograms were evaluated in a masked fashion by an examiner (SMB) who had no knowledge of retinal circulatory results. At entry to the study, two patients had no observable retinopathy; nine patients had microaneurysms only, with only 1 to 10 observable microaneurysms present; 13 patients had background retinopathy that consisted of varying combinations of microaneurysms, hemorrhages, exudates, capillary dilation, and macular leakage; clinically observable capillary occlusion was found in two of these patients. In terms of the ETDRS Final Retinopathy Severity Scale, which is based on color fundus photography only,<sup>8</sup> the severity of retinopathy at entry ranged from level 10 (retinopathy absent) to level 35 (mild nonproliferative retinopathy).

At the final visit, four patients had no observable retinopathy; two patients had microaneurysms only, with only 1 to 10 observable microaneurysms present; 17 patients had background retinopathy that consisted of varying combinations of microaneurysms, hemorrhages, exudates, intraretinal microvascular abnormalities (IRMA), capillary dilation, and macular leakage; clinically observable capillary occlusion was found in six of these patients. One patient had retinal neovascularization in addition to the signs of background retinopathy. In terms of the ETDRS Final Retinopathy Severity Scale, the severity of retinopathy at the final visit ranged from level 10 (retinopathy absent) to level 61 (mild proliferative retinopathy).

To account for small changes in retinopathy in the eye studied, we developed a scoring system that used information from color fundus photographs and fluorescein angiograms. Using fundus photographs, a partial retinopathy score was generated by counting 1 point for the presence of dot or blot hemorrhages, hard or soft exudates, venous beading, vessel loops, neovascularization on the optic disc, retinal neovascu-

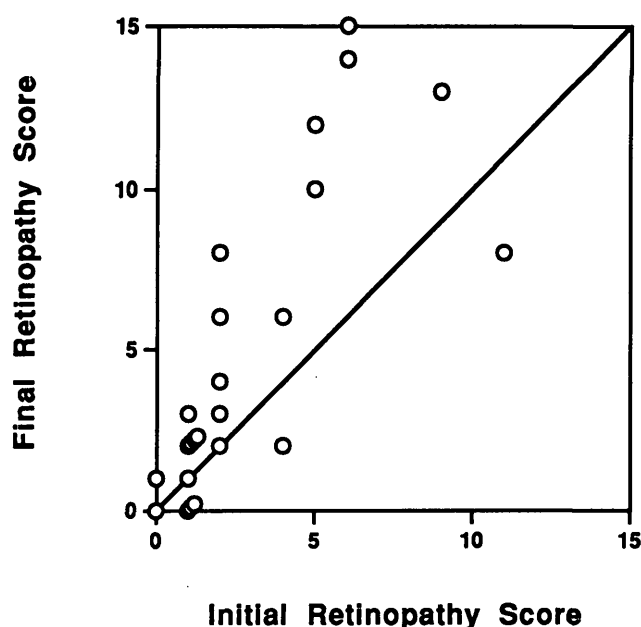


FIGURE 1. Final retinopathy score plotted as a function of the initial retinopathy score for each patient. Shown is the identity line representing no change in retinopathy.

larization, or macular thickening. Using fluorescein angiograms, an additional partial retinopathy score was generated by counting 1 point for the presence of microaneurysm leakage, macular leakage, diffuse or cystoid macular edema, IRMA, IRMA leakage, capillary dilatation, or capillary occlusion in the periphery or arcade. Also, the presence of 1 to 10 microaneurysms was counted as 1 point, 10 to 100 microaneurysms as 2 points, or more than 100 microaneurysms as 3 points. An aggregate retinopathy score was obtained by summing the two partial scores. The maximum possible aggregate retinopathy score was 21 points.

At entry to the study, retinopathy scores in the 24 eyes studied ranged from 0 to 11 points. During the follow-up period, the retinopathy scores increased in 16 eyes, remained the same in three, and decreased in five. Three of the five eyes in which the retinopathy scores decreased changed from a score of 1 point to a score of 0 points. Figure 1 shows the final retinopathy score plotted as a function of the initial retinopathy score for each patient. The maximum final retinopathy score was 15 points.

Before laser Doppler testing at each visit, subjects' pupils were dilated with 1% tropicamide. Monochromatic (575 nm) fundus photographs were taken of each eye. The methodology of our application of the laser Doppler technique to measurement of centerline blood speed in retinal arteries has been described in detail.<sup>9</sup> Modifications to the methodology have been described.<sup>10</sup> Our projection micrometry technique for measurement of arterial diameters using

monochromatic photographs also has been described.<sup>11</sup>

Blood flow in an individual retinal artery was calculated as  $\text{Flow} = \bar{V} \times \text{Area}/2$ , where  $\bar{V}$  is the time average of the centerline blood speed during the cardiac cycle, and Area is the cross-sectional area of the retinal artery at the laser Doppler measurement site.<sup>12</sup> The area was calculated from the arterial diameter assuming a circular cross-section.

Laser Doppler measurements were obtained from a temporal retinal artery in one eye of each subject. The arteries chosen for measurement had relatively straight segments that were sufficiently distant from adjacent vessels. Measurement sites were generally between the disc margin and the first bifurcation. The location of the measurement site was recorded on the color fundus photograph for later reference. Eighteen right eyes and six left eyes were studied. Measurements were obtained from 14 superior temporal arteries and 10 inferior temporal arteries. Retinal circulatory measurements were obtained without knowledge of the retinopathy evaluation of the patients. The statistical significance of differences in arterial diameter, centerline blood speed, and retinal blood flow between male and female, right and left eye studied, and superior and inferior vessels measured was determined using unpaired *t*-tests.

The change in retinal blood flow in the measured artery of each patient during the follow-up period was determined by computing the slope of the serial blood flow measurements using linear regression analysis. Linear regression analysis also was used to compute the slope of the change in glycosylated hemoglobin, daily insulin dosage, intraocular pressure, mean blood pressure, heart rate, and blood glucose during the follow-up period for each patient. Multiple linear regression analysis was then used to study the relationship between the retinal blood flow slopes and median age, median duration of diabetes during the follow-up period, gender, retinal blood flow at entry to the study, glycosylated hemoglobin slopes, daily insulin dosage slopes, intraocular pressure slopes, mean blood pressure slopes, heart rate slopes, and blood glucose slopes. Spearman correlation analysis was used to evaluate the relationships between the initial retinopathy score and the duration of disease at entry, and between the retinal blood flow slopes and the median retinopathy score. To aid in interpreting the results, the patients were divided into two groups, those with decreasing retinal blood flow and those with increasing retinal blood flow. The statistical significance of differences in arterial diameter, centerline blood speed, and retinal blood flow between the initial and final measurements in each group was de-

terminated using paired *t*-tests.  $P \leq 0.05$  was considered statistically significant.

## RESULTS

At entry to the study, arterial diameter at the laser Doppler measurement sites was  $138 \pm 3 \mu\text{m}$  (mean  $\pm$  SEM), and centerline blood speed was  $4.9 \pm 0.3 \text{ cm/second}$ . The corresponding blood flow in the measured artery was  $23.6 \pm 1.9 \mu\text{l/minute}$ . There were no statistically significant differences in these retinal circulatory parameters related to gender, eye studied, or superior versus inferior vessels measured.

Spearman correlation analysis showed that the initial retinopathy score was directly related to the duration of diabetes at entry to the study ( $P = 0.67$ ;  $P = 0.001$ ). As expected, there was an increasing severity of retinopathy with increasing duration of diabetes.

The slopes of the change in retinal blood flow during the follow-up period were negative in 15 patients and positive in nine patients. Figures 2a and 2b show the retinal blood flow plotted as a function of the duration of diabetes for two patients, one with negative retinal blood flow slope and one with positive retinal blood flow slope. The patient with negative slope was a 24-year-old woman who, at entry to the study, had a 16-year history of diabetes. Initially, her retinopathy consisted of approximately 30 microaneurysms; therefore, the retinopathy score was 2 points. Measurements were obtained at entry and annually for 5 years from a site along the superior temporal retinal artery of the right eye. Throughout this series of measurements, the arterial diameter showed no appreciable change. Centerline blood speed was  $6.9 \text{ cm/second}$  at entry and decreased to  $1.7 \text{ cm/second}$  at the final visit. The retinal blood flow was  $33.7 \mu\text{l/minute}$  at entry and decreased to  $8.4 \mu\text{l/minute}$  at the final visit. At the final visit, the retinopathy consisted of approximately 50 microaneurysms and microaneurysm leakage; the retinopathy score increased to 3 points. The slope of the linear regression fit to the blood flow data was  $-6.1 \mu\text{l/minute per year}$ .

The patient with positive slope, who was the only patient in whom retinal neovascularization developed during the follow-up period, was a 21-year-old woman with a 20-year history of diabetes at entry to the study. Her retinopathy score was 6 points at the first visit. Approximately 60 microaneurysms, microaneurysm leakage, macular leakage, capillary dilatation, and soft exudates were observed. Measurements were obtained at entry and annually for 3 years from a site along the inferior temporal retinal artery of the right eye. There were no appreciable changes in arterial diameter during follow up. Centerline blood speed was  $2.5 \text{ cm/seconds}$  at entry and increased to  $5.3 \text{ cm/seconds}$  at

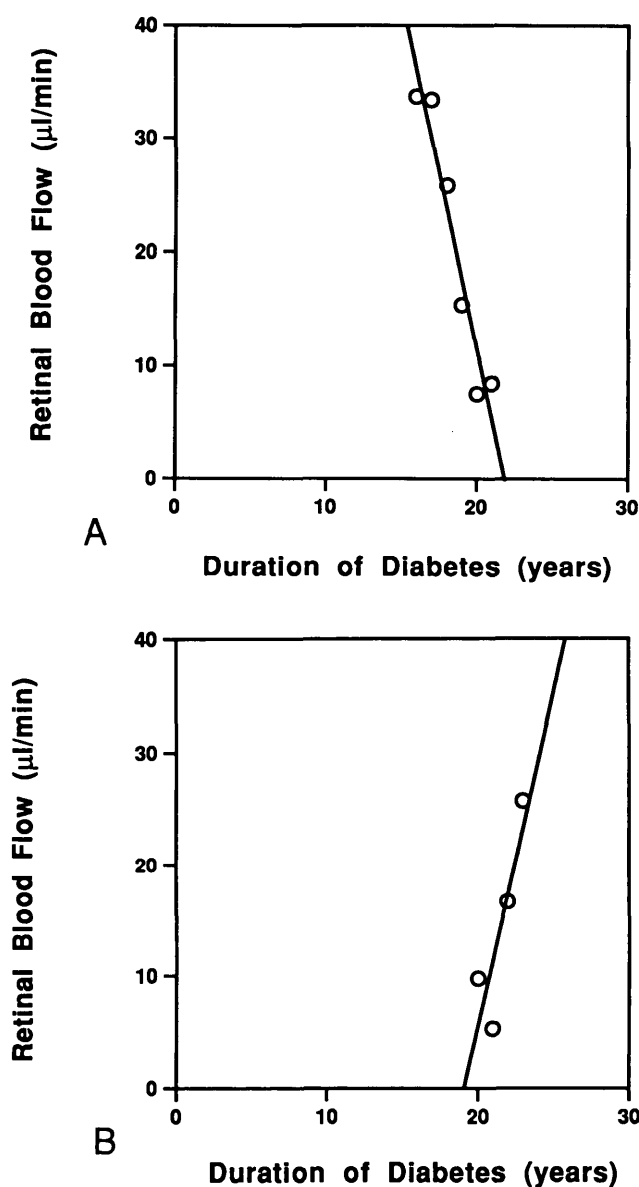


FIGURE 2. Retinal blood flow plotted as a function of duration of diabetes for two patients, one with negative retinal blood flow slope (A) and one with positive retinal blood flow slope (B). The solid lines represent the linear regression fits to the data.

the final visit. The retinal blood flow was  $9.7 \mu\text{l/minutes}$  at entry and increased to  $25.7 \mu\text{l/minutes}$  at the final visit. The retinopathy score increased to 15 points during follow up. At the final visit, approximately 120 microaneurysms, microaneurysm leakage, macular leakage, diffuse and cystoid macular edema, IRMA, IRMA leakage, capillary occlusion in the periphery and arcade, dot hemorrhages, hard exudates, soft exudates, and retinal neovascularization were observed. The slope of the linear regression fit to the blood flow data was  $5.9 \mu\text{l/minute per year}$ .

Multiple linear regression analysis was used to de-

termine whether the retinal blood flow slopes measured in the entire group of study subjects were related to median age, median duration of diabetes during the follow-up period, gender, initial retinal blood flow, glycosylated hemoglobin slopes, daily insulin dosage slopes, intraocular pressure slopes, mean blood pressure slopes, heart rate slopes, or blood glucose slopes. Stepwise elimination of nonsignificant variables led to an optimum model ( $R^2 = 0.56$ ;  $P = 0.0002$ ) that included only initial retinal blood flow (coefficient =  $-0.26 \pm 0.07$ ;  $P = 0.001$ ) and median duration of diabetes (coefficient =  $0.22 \pm 0.09$ ;  $P = 0.02$ ). Figure 3a shows the retinal blood flow slope plotted as a function of the initial retinal blood flow. The more negative slopes are associated with the higher initial retinal blood flows, and the more positive slopes are associated with the lower initial flows. Figure 3b shows the retinal blood flow slope plotted as a function of the median duration of diabetes. The linear regression fit crosses the zero slope line at approximately 20 years median duration, indicating that the retinal blood flow ceases to decrease and begins to increase approximately 20 years of diabetes.

Because the retinopathy score was dependent on the duration of disease, it was not included in the factors of the multiple linear regression analysis. Spearman correlation analysis was performed to determine whether the retinal blood flow slopes were related to the retinopathy scores. There was a positive correlation between the retinal blood flow slopes and the median retinopathy scores during the follow-up period ( $P = 0.47$ ;  $P = 0.02$ ). Results indicate that the more negative retinal blood flow slopes are associated with the presence of the least amount of retinopathy.

To aid in visualizing and interpreting the blood flow results, the patients were divided into two groups, those with decreasing retinal blood flow and those with increasing retinal blood flow. Table 1 shows the average values for centerline blood speed, the corresponding blood flow, and the duration of diabetes at the initial and final measurements in the two groups. In the group with decreasing retinal blood flow, centerline blood speed was 38% lower ( $P = 0.0006$ ), and the blood flow was 40% lower ( $P = 0.0001$ ) at the final measurements than at the initial measurements. In the group with increasing retinal blood flow, centerline blood speed was 28% higher ( $P = 0.01$ ), and the retinal blood flow was 42% higher ( $P = 0.003$ ) at the final measurements than at the initial measurements. There were no statistically significant differences in arterial diameter in either group between initial and final measurements. Figure 4 shows the initial and final retinal blood flow in each group plotted as a function of the duration of diabetes. On average, the retinal blood flow initially decreases, and it

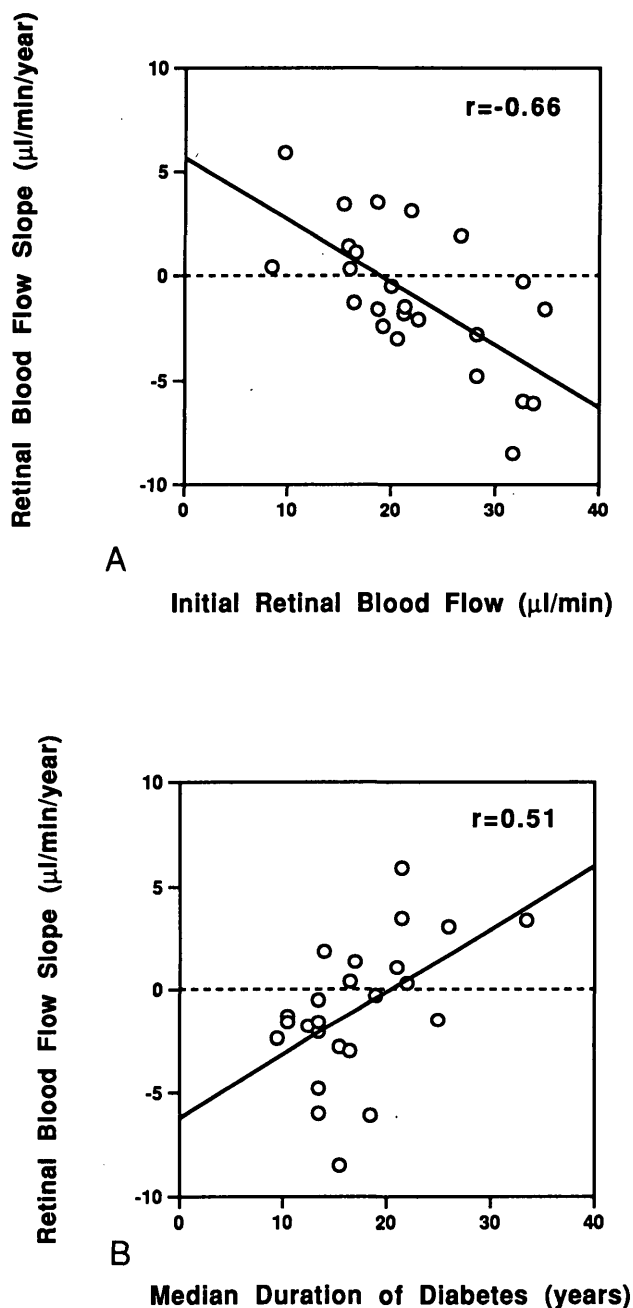


FIGURE 3. Retinal blood flow slope plotted as a function of initial retinal blood flow (A) and the median duration of diabetes during the follow-up period (B). The solid line represents the linear regression fit to the data, and the dashed line represents zero slope.

begins to increase with increasing duration of diabetes.

## DISCUSSION

The advantages inherent in a long-term, follow-up study have provided the means for a more complete understanding of retinal blood flow changes in patients with type I diabetes. Results indicate that the

TABLE 1. Blood Speed, Blood Flow, and Duration of Diabetes

	Decreasing Group (n = 15)		Increasing Group (n = 9)	
	Initial	Final	Initial	Final
Centerline blood speed (cm/sec)	5.5 ± 0.3	(P = 0.0006)*	3.4 ± 0.4	3.9 ± 0.3
Blood flow rate (μl/min)	25.5 ± 1.7	(P = 0.0001)*	15.2 ± 2.0	16.6 ± 1.9
Duration of diabetes (years)	12.5 ± 1.1		20.0 ± 2.0	22.9 ± 1.9

Values are mean ± SEM.

\*Comparison between the initial and the final measurements (two-tailed paired *t*-test).

changes in retinal blood flow, quantified as the retinal blood flow slope, are significantly related to the duration of diabetes; that the changes in retinal blood flow also are related to initial retinal blood flow values; that the changes in retinal blood flow are related to the onset and progression of retinopathy in these patients.

Results show that in the patients with the shortest durations of diabetes, the highest retinal blood flow values are present, along with the least amount of retinopathy. At the same time, the decrease in retinal blood flow is the most rapid in these patients. In the patients with slightly longer durations of diabetes, retinal blood flow values are lower, and retinopathy is slightly more severe. The decrease in retinal blood flow is less rapid in these patients. At approximately 20 years of diabetes, the lowest retinal blood flow val-

ues are present, as is more severe retinopathy. At this point, blood flow in the major retinal arteries ceases to decrease and begins to increase.

Our findings of decreasing arterial centerline blood speed and blood flow with increasing duration of diabetes are consistent with results obtained in our previous cross-sectional study<sup>1</sup> of patients with type I diabetes. In that study, we reported a negative correlation between centerline blood speed and duration of diabetes in the range 7 to 20 years. Both sets of results are consistent with the findings of Rimmer et al.,<sup>4</sup> who reported a progressive slowing of the blood speeds in the perifoveal capillaries over a time interval of several years in patients with background retinopathy. In the cross-sectional study, the average blood flow measured in a major temporal retinal artery in 39 patients was  $17.5 \pm 1.3 \mu\text{l}/\text{minute}$ . In this follow-up study, as indicated above, the initial retinal blood flow measured in the 24 patients was  $23.6 \pm 1.9 \mu\text{l}/\text{minute}$ . Twenty-one patients in the follow-up study were also subjects in the cross-sectional study, and in 18 of these 21 patients, the initial retinal blood flow value was used in the cross-sectional study. The higher initial retinal blood flow values measured in this study were caused mainly by the fact that the arterial diameters ( $138 \pm 3 \mu\text{m}$ ,  $n = 24$ ) were larger in this study than in the cross-sectional study ( $132 \pm 3 \mu\text{m}$ ,  $n = 39$ ). As we previously reported,<sup>12</sup> such a difference in diameter can account for a difference in blood flow of as much as 20%.

It is interesting to compare the initial retinal blood flow values measured in this study to retinal blood flow measured in subjects without diabetes of comparable age. As we have previously reported,<sup>12</sup> the retinal blood flow in a  $138\text{-}\mu\text{m}$  diameter retinal artery in a young, healthy subject without diabetes is approximately  $33 \mu\text{l}/\text{minute}$ . Thus, the initial blood flow values measured in the patients with diabetes in this study were nearly 30% lower than in subjects without diabetes. Although large changes in retinal blood flow were

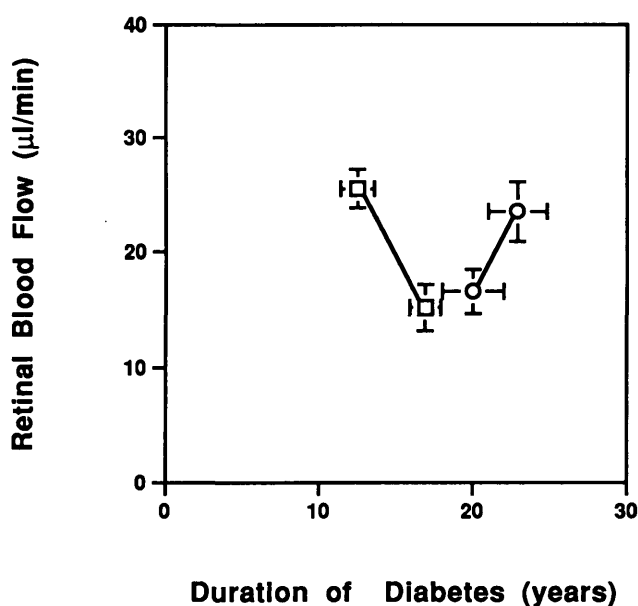


FIGURE 4. Initial and final retinal blood flow in patients with decreasing flow (open squares) and in patients with increasing flow (open circles) plotted as a function of the duration of diabetes. Results are shown as mean ± SEM.

measured in the patients in this study during the 2- to 6-year follow-up period, only minimal changes in retinal blood flow are expected in subjects without diabetes over such a period. A preliminary study<sup>13</sup> has shown that retinal blood flow decreases by only approximately 10% between the ages of 30 and 56 years in normal subjects.

Our finding of rapidly decreasing blood flow in the patients with no retinopathy or minimal retinopathy with short duration of diabetes is also consistent with the results reported in our cross-sectional study.<sup>1</sup> In that study, the blood speed in patients with no clinically observable retinopathy was already, on average, 33% lower than in control subjects without diabetes whose retinal arteries were of the same diameters.

The decreasing blood flow measured in the major retinal arteries is a direct indication of an increasing resistance to flow through the retinal vascular network. Such an increase in resistance appears to begin before the appearance of retinopathy. It has been speculated that microaneurysm formation, usually the first sign of retinopathy, is caused by stasis and engorgement of the retinal capillaries.<sup>14</sup> Capillary obstruction is likely caused by abnormalities of the endothelial cells lining the vessel wall, to blood rheologic abnormalities, or to a combination of both factors.<sup>15</sup>

Blood rheologic abnormalities, including decreased red cell deformability,<sup>16</sup> increased red cell<sup>17</sup> and platelet<sup>18</sup> aggregation, and increased plasma viscosity,<sup>19</sup> have been reported widely in patients with diabetes. A more intrinsic abnormality, however, appears to be endothelial cell dysfunction. Abnormal levels of prostacyclin,<sup>20</sup> von Willebrand factor,<sup>15</sup> and plasmin activator<sup>21</sup> have been measured in patients with diabetes. These abnormalities tend to compromise the anti-thrombotic and fibrinolytic activity of the vascular endothelium, leading to the obstruction of retinal capillaries. Such obstruction has been observed: Sural nerve biopsies from patients with diabetic neuropathy have revealed fibrinous thrombi in small blood vessels, as well as desquamation of endothelial cells from the vessel wall.<sup>22</sup>

An alternative mechanism linking the vascular endothelium to increased resistance to flow involves the polypeptide endothelin,<sup>23</sup> a potent vasoconstrictor produced by endothelial cells. The action of endothelin on retinal pericytes<sup>24</sup> and small retinal arteries<sup>25</sup> has been demonstrated. Furthermore, it has been shown that elevation of glucose levels to those typically encountered in patients with diabetes enhances the secretion of endothelin.<sup>26</sup> If this occurs in the retina, the resultant vasoconstriction would result in increased microvascular resistance and reduced retinal blood flow.

The observation that, on average, blood flow in

the major retinal arteries ceases to decrease and begins to increase as duration of diabetes becomes longer and retinopathy becomes more severe is consistent with our previous finding<sup>27</sup> of relative increases in the retinal blood flow in three patients with diabetes during the progression from background to proliferative retinopathy. In the current study, six of the patients showed a transition from decreasing retinal blood flow to increasing retinal blood flow during their follow-up periods. None of the patients showed a transition from increasing blood flow to decreasing blood flow. Four were categorized as having a decreasing retinal blood flow slope, and two were categorized as having an increasing blood flow slope. An example was shown in Figure 2b. The initial retinal blood flow measured in the patient at 20 years duration of diabetes was 9.7  $\mu\text{l}/\text{minute}$ . The retinopathy score was 6 points. One year later, at the second visit, the retinal blood flow decreased to 5.2  $\mu\text{l}/\text{minute}$ , whereas the retinopathy score increased to 12 points. At the third visit 1 year after that, the retinal blood flow increased to 16.6  $\mu\text{l}/\text{minute}$ , and the retinopathy score increased to 15 points. At the final visit 1 year later, the retinal blood flow continued to increase to 25.7  $\mu\text{l}/\text{minute}$ , whereas the retinopathy score remained at 15 points.

The beginning of an increase in retinal blood flow suggests that there is a beginning of a net decrease in the resistance to flow. One explanation for the net decrease is that short-circuiting of the obstructed retinal capillary network begins to occur during the progression of diabetic retinopathy. This explanation is supported by histopathologic studies<sup>28,29</sup> that clearly show areas of capillary closure are traversed by preferential dilated anastomotic channels that act as shunts between arterioles and venules. The beginning of the increase in blood flow in the major feeding arteries thus may be an indication that more blood begins to flow through the preferential channels, bypassing obstructed portions of the capillary network. In this study, areas of capillary nonperfusion were observed in 5 of 9 patients in whom retinal blood flow increased during the follow-up period. Capillary nonperfusion was observed in only 2 of 15 patients in whom retinal blood flow decreased during the follow-up period. This result clearly suggests an association between increasing retinal blood flow and overt capillary nonperfusion.

Autoregulatory mechanisms may be involved as well in producing the net decrease in the resistance to flow that we have observed. Because retinal vessels lack sympathetic innervation, autoregulation is controlled by local factors, such as pH,  $\text{PCO}_2$ , and particularly tissue  $\text{PO}_2$ . Capillary nonperfusion would produce retinal hypoxia. Patients with diabetes also have

decreased erythrocyte oxygen delivery.<sup>30,31</sup> Increasing retinal blood flow, then, could be related to attempts by autoregulatory mechanisms to provide adequate oxygenation in response to the increased oxygen demands of the retinal tissue. Grunwald et al,<sup>32</sup> however, reported that the autoregulatory response to oxygen already is impaired in patients with diabetes with no retinopathy and progressively more impaired with advancing retinopathy. It is unlikely, therefore, that autoregulatory mechanisms are solely responsible for the increasing retinal blood flow we observed in the patients with more advanced retinopathy.

In summary, our results indicate that there is a transition from decreasing retinal blood flow to increasing retinal blood flow in patients with type I diabetes that depends on the duration of diabetes and the severity of retinopathy. These results are based on follow-up measurements in 24 patients of retinal blood flow and retinopathy severity over a period ranging from 2 to 6 years. Ideally, in such a study, it would have been advantageous to follow up all the patients for the longest possible period. Nevertheless, the results do indicate the general nature of the sequence of retinal blood flow changes that occur in these patients. Blood flow changes are related to the complex pathologic alterations that occur in the diabetic retina.

### Key Words

duration of diabetes, laser Doppler technique, patients with type I diabetes, retinal arterial blood speed, retinal blood flow

### References

1. Feke GT, Buzney SM, Ogasawara H, et al. Retinal circulatory abnormalities in type I diabetes. *Invest Ophthalmol Vis Sci*. 1994;35:2968–2975.
2. Arend O, Wolf S, Jung F, et al. Retinal microcirculation in patients with diabetes mellitus: Dynamic and morphological analysis of perifoveal capillary network. *Br J Ophthalmol*. 1991;75:514–518.
3. Grunwald JE, Riva CE, Sinclair SH, Brucker AJ, Petrig BL. Laser Doppler velocimetry study of retinal circulation in diabetic mellitus. *Arch Ophthalmol*. 1986;104:991–996.
4. Rimmer T, Fallon TJ, Kohner EM. Long-term follow-up of retinal blood flow in diabetes using the blue light entoptic phenomenon. *Br J Ophthalmol*. 1989;73:1–5.
5. Gabbay KH, Hasty K, Breslow JL, Ellison RC, Bunn HF, Gallop PM. Glycosylated hemoglobins and long-term blood glucose control in diabetes mellitus. *J Clin Endocrinol Metab*. 1977;44:859–864.
6. The Early Treatment Diabetic Retinopathy Study Research Group. Grading diabetic retinopathy from stereoscopic color fundus photographs—an extension of the modified Airlie House classification. ETDRS report number 10. *Ophthalmology*. 1991;98:807–822.
7. The Early Treatment Diabetic Retinopathy Study Research Group. Classification of diabetic retinopathy from fluorescein angiograms. ETDRS report number 11. *Ophthalmology*. 1991;98:807–822.
8. The Early Treatment Diabetic Retinopathy Study Research Group. Fundus photographic risk factors for progression of diabetic retinopathy. ETDRS report number 12. *Ophthalmology*. 1991;98:823–833.
9. Feke GT, Goger DG, Tagawa H, Delori FC. Laser Doppler technique for absolute measurement of blood speed in retinal vessels. *IEEE Trans Biomed Eng*. 1987;34:673–680.
10. Ogasawara H, Feke GT, Yoshida A, Milbocker MT, Weiter JJ, McMeel JW. Retinal blood flow alterations associated with scleral buckling and encircling procedures. *Br J Ophthalmol*. 1992;76:275–279.
11. Delori FC, Fitch KA, Feke GT, Deupree DM, Weiter JJ. Evaluation of micrometric and microdensitometric methods for measuring the width of retinal vessel images on fundus photographs. *Graefes Arch Clin Exp Ophthalmol*. 1988;226:393–399.
12. Feke GT, Tagawa H, Deupree DM, Goger DG, Sebag J, Weiter JJ. Blood flow in the normal human retina. *Invest Ophthalmol Vis Sci*. 1989;30:58–65.
13. Feke GT, Yoshida A, Ogasawara H, Goger DG. Retinal hemodynamics in middle-aged normal subjects. ARVO Abstracts. *Invest Ophthalmol Vis Sci*. 1990;31:382.
14. Ashton N. Studies of the retinal capillaries in relation to diabetic and other retinopathies. *Br J Ophthalmol*. 1963;47:521–538.
15. Kohner EM, Porta M. Vascular abnormalities in diabetes and their treatment. *Trans Ophthalmol Soc UK*. 1980;100:440–444.
16. McMillan DE, Utterback NG, LaPuma J. Reduced erythrocyte deformability in diabetes. *Diabetes*. 1978;27:895–901.
17. Schmid-Schönbein H, Volger E. Red-cell aggregation and red-cell deformability in diabetes. *Diabetes*. 1976;25(suppl 2):897–902.
18. Sagel J, Colwell JA, Crook L, Laimins M. Increased platelet aggregation in early diabetes mellitus. *Ann Intern Med*. 1975;82:733–738.
19. McMillan DE. Plasma protein changes, blood viscosity, and diabetic microangiopathy. *Diabetes*. 1976;25:858–864.
20. Colwell JA, Winocour PD, Lopes-Virella M, Halushka PV. New concepts about the pathogenesis of atherosclerosis in diabetes mellitus. *Am J Med*. 1983;75(suppl 5B):67–80.
21. Almér LO, Pandolfi M. Fibrinolysis and diabetic retinopathy. *Diabetes*. 1976;25(suppl 2):807–810.
22. Williams E, Timperley WR, Ward JD, Duckworth T. Electron microscopical studies of vessels in diabetic peripheral neuropathy. *J Clin Pathol*. 1980;33:462–470.
23. Yanagisawa M, Kurihara H, Kimura S, et al. A novel potent vasoconstrictor peptide produced by vascular endothelial cells. *Nature*. 1988;332:411–415.
24. Takahashi K, Brooks RA, Kanse SM, Ghatei MA, Kohner EM, Bloom SR. Production of endothelin 1



- by cultured bovine retinal endothelial cells and presence of endothelin receptors on associated pericytes. *Diabetes*. 1989;38:1200–1202.
25. Nyborg NCB, Prieto D, Benedito S, Nielsen PJ. Endothelin-1-induced constriction of bovine retinal small arteries is reversible and abolished by nitrendipine. *Invest Ophthalmol Vis Sci*. 1991;32:27–31.
26. Yamauchi T, Ohnaka K, Takayanagi R, Umeda F, Nawata H. Enhanced secretion of endothelin-1 by elevated glucose levels from cultured bovine aortic endothelial cells. *FEBS Lett*. 1990;267:16–18.
27. Fekete GT, Tagawa H, Yoshida A, et al. Retinal circulatory changes related to retinopathy progression in insulin dependent diabetes mellitus. *Ophthalmology*. 1985;92:1517–1522.
28. Cogan DG, Kuwabara T. Capillary shunts in the pathogenesis of diabetic retinopathy. *Diabetes*. 1963;12:293–300.
29. Cunha-Vaz JG. Diabetic retinopathy: Human and experimental studies. *Trans Ophthalmol Soc UK*. 1972;92:111–124.
30. Ditzel J. Affinity hypoxia as a pathogenetic factor of microangiopathy with particular reference to diabetic retinopathy. *Acta Endocrinol*. 1980;94(suppl 238):39–55.
31. Ditzel J. Oxygen transport impairment in diabetes. *Diabetes*. 1976;25(suppl 2):832–838.
32. Grunwald JE, Riva CE, Brucker AJ, Sinclair SH, Petrig BL. Altered retinal vascular response to 100% oxygen breathing in diabetes mellitus. *Ophthalmology*. 1984;91:1447–1452.