

Cerebral Small Vessel Disease in Branch Retinal Artery Occlusion

Kwan Hyuk Cho,¹ Chi Kyung Kim,² Se Joon Woo,¹ Kyu Hyung Park,¹ and Sang Jun Park¹

¹Department of Ophthalmology, Seoul National University College of Medicine, Seoul National University Bundang Hospital, Seongnam, Republic of Korea

²Department of Neurology, Korea University Guro Hospital, Seoul, Republic of Korea

Correspondence: Sang Jun Park, Department of Ophthalmology, Seoul National University Bundang Hospital, #300 Gumi-dong, Bundang-gu, Seongnam, Gyeonggi-do 463-707, Republic of Korea; sangjunpark@snu.ac.kr.

KHC and CKK contributed equally to the work presented here and therefore should be regarded as equivalent authors.

Submitted: June 9, 2016
Accepted: August 29, 2016

Citation: Cho KH, Kim CK, Woo SJ, Park KH, Park SJ. Cerebral small vessel disease in branch retinal artery occlusion. *Invest Ophthalmol Vis Sci*. 2016;57:5818–5824. DOI:10.1167/iov.16-20106

PURPOSE. We investigated the pathophysiology of branch retinal artery occlusion (BRAO) by evaluating the retina, brain, and carotid artery in patients with BRAO.

METHODS. This study was a retrospective registry study. We used 46 eyes from 46 patients with acute BRAO and evaluated the medical history, including previous cardiovascular disease, and compared brain magnetic resonance images (MRI) and carotid artery stenosis state between the embolic BRAO group and nonembolic BRAO group. We measured differences in cerebrovascular characteristics, including brain MRI, according to the existence of retinal emboli.

RESULTS. The embolic BRAO group tended to have a significantly higher likelihood of cardiovascular disease history, including ischemic heart disease and smoking history ($P = 0.018$ and $P < 0.001$, respectively). In addition, the embolic group had a higher frequency of acute cerebral infarctions and stenotic carotid arteries ($P = 0.017$ and $P = 0.028$, respectively). Although the overall frequency of cerebral small vessel disease (SVD) did not differ between embolic and nonembolic groups, the nonembolic BRAO group showed a significantly higher prevalence of cerebral SVD without large vessel pathology ($P = 0.008$).

CONCLUSIONS. Patients with BRAO showed different cerebrovascular characteristics following retinal emboli, including brain MRI findings. The results suggest that we must consider SVD etiology as well as large vessel disease mechanisms in the pathophysiology of BRAO.

Keywords: branch retinal artery occlusion, cerebral small vessel disease, brain magnetic resonance image, retinal emboli

Retinal artery occlusion (RAO) is a relatively common, visually disabling ocular vascular occlusive disorder, and branch retinal artery occlusion (BRAO) is estimated to account for approximately 38% of all acute RAO cases.^{1–4} Emboli or in situ blood clots on lipid plaques are considered typical causes of vascular occlusive disease, and similar mechanisms apply to RAO; thus, a large vessel disease (LVD) etiology and embolism from carotid artery plaques may be the most common pathology of RAO.^{5,6} Although its layered anatomy and metabolic activity is different from that in the brain, the retina differentiates from the diencephalon during embryonic development; previously, some studies reported that it shares a few physiological characteristics with the brain.^{7–11}

The health-related concerns associated with RAO include not only vision loss but also subsequent or concomitant cardiovascular disease, such as stroke or acute myocardial infarction (AMI). Retinal ischemia is therefore an urgent indication for neuroimaging and systemic vascular risk assessment as part of seeking LVD.^{12–14} However, the LVD mechanism hypothesis typified by emboli does not explain all BRAO cases, and the dimensions of the branch retinal artery provide relevant clues to the additional pathophysiology of BRAO.

The branch retinal artery is classified as an arteriole, that is, smaller than a small artery and larger than a capillary.³ It seems conceivable that pathologic conditions affecting the arterioles of the brain might similarly affect the branch retinal artery and

that, in turn, the occurrence of BRAO could be attributable to the main pathophysiology of the emboli. However, few data address the pathophysiology of BRAO in this regard. Interestingly, similar pathologic changes are manifested in the brain in cerebral small vessel disease (SVD), including white matter hyperintensities (WMHs), cerebral microbleeds (CMBs), and silent lacunar infarcts. As these small arteries and arterioles are not easily visualized using conventional brain magnetic resonance imaging (MRI)/magnetic resonance imaging angiography (MRA), brain MRI findings such as WMHs, CMBs, and radiologic lacunar infarctions have been assumed to indicate SVD.^{15–18} These cerebral SVDs are closely related to the risk of future stroke and cognitive impairment,^{19–22} and may be an additional explanation for the pathophysiology of BRAO. Here, we investigated the “dark continent” of a potentially additional pathophysiological mechanism for BRAO by brain MRI and carotid artery status along with fundus photographs.

METHODS

Eligibility Criteria

We used the RAO registry database at the Seoul National University Bundang Hospital, which included 304 eyes of RAO patients presenting with acute vision loss and/or visual field defect within 14 days from January 2009 to October 2014. The



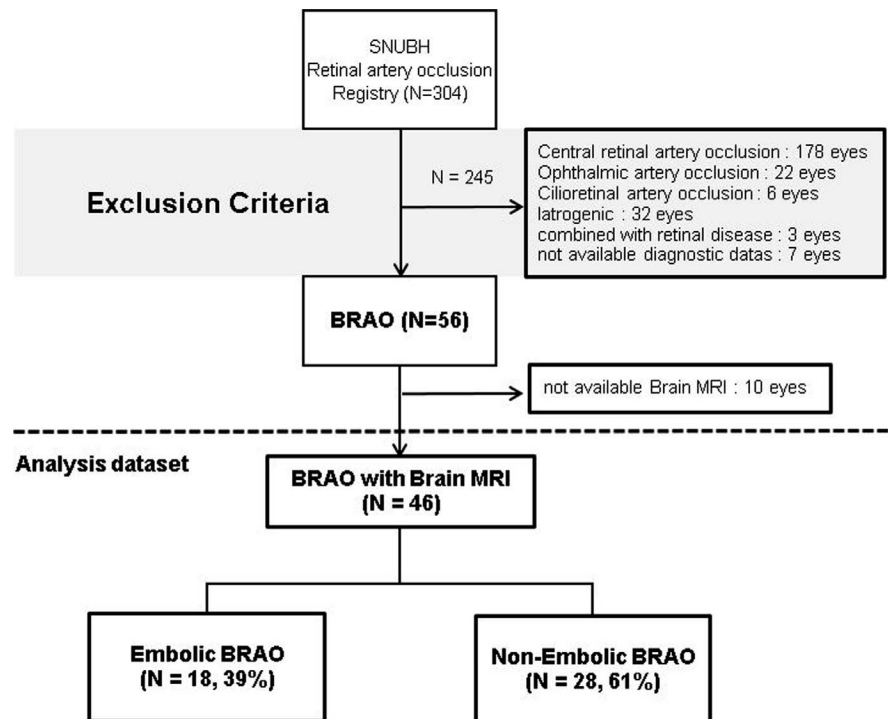


FIGURE 1. Flow diagram showing the selection and subgrouping process of the enrolled eyes with branch retinal artery occlusion. Emboli, visible emboli on fundus photography at initial visit; SNUBH, Seoul National University, Bundang Hospital; BRAO, branch retinal artery occlusion; MRI, magnetic resonance image; Iatrogenic, retinal artery occlusion by iatrogenic cause (e.g., cosmetic filler injection).

registry consisted of patients with central RAO ($n = 178$), ophthalmic artery occlusion ($n = 22$), cilioretinal artery occlusion ($n = 6$), and iatrogenic cosmetic filler-induced RAO ($n = 32$); and patients without ophthalmic examination ($n = 7$), BRAO combined with other retinal disease ($n = 3$), and BRAO ($n = 56$). Among these, we chose patients with BRAO and initial brain MRI data ($n = 46$); the initial brain MRI needed to have been performed within 2 weeks of the first visit. The typical point of vascular blockade in central RAO and ophthalmic artery occlusion is located behind the optic disc, which makes it impossible to judge the existence of emboli. In addition, as vasculitis concerns development of cilioretinal artery occlusion, we excluded the three diseases from our

analysis dataset. Figure 1 provides a flow chart for eligibility criteria and following analyses.

Demographics, Medical Histories, and Ophthalmic Evaluation

All patients underwent slit-lamp biomicroscopy, indirect fundus examination, fundus photography (Vx-10; Kowa Optimed, Tokyo, Japan, or Optos PLC, Dunfermline, Scotland, UK), and fluorescein angiography (FA) (Vx-10) at the initial visit. We collected demographics and medical histories (e.g., medical history of hypertension, diabetes mellitus, dyslipidemia, smoking, and previous cardiovascular disease including

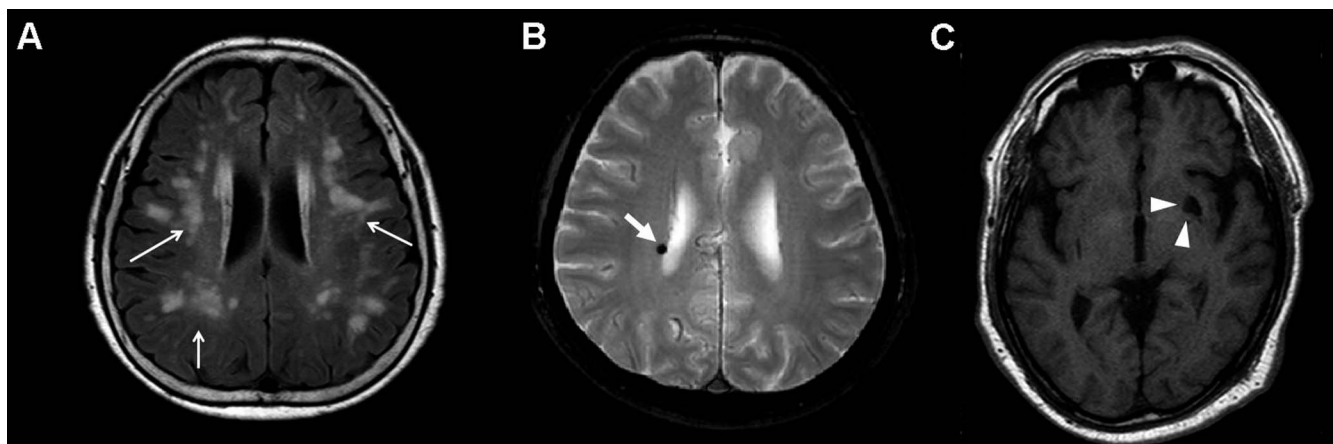


FIGURE 2. Representative brain MRI of cerebral small vessel disease in patients with branch retinal artery occlusion (BRAO). (A) White matter hyperintensities on MRI (FLAIR image), classified grade 3 by Fazekas scale (white arrows). (B) A cerebral microbleed shown in T2-weighted MRI (white arrow). (C) Silent lacunar infarct in the left thalamus in a T1-weighted MRI (white arrow). MRI, magnetic resonance image; FLAIR, fluid-attenuated inversion recovery.

TABLE 1. Clinical Characteristics and Underlying Diseases in Patients With Branch Retinal Artery Occlusion (BRAO) and Comparison According to Emboli Existence

Characteristics	Embolic BRAO (<i>N</i> = 18, 39%)	Nonembolic BRAO (<i>N</i> = 28, 61%)	<i>P</i> Value
Age, mean, y	66.6 ± 12.7 (32–73)	58.1 ± 19.1 (14–92)	0.070*
Sex, male (%)	13 (72)	22 (79)	0.440†
Time from symptom onset to initial diagnosis, h	89.1 ± 87.9 (1–288)	94.9 ± 114.6 (1–350)	0.687*
Past medical history, <i>N</i> (%)			
Hypertension	15 (83)	20 (71)	0.486†
Diabetes	7 (39)	9 (32)	0.754†
Dyslipidemia	8 (44)	8 (29)	0.347†
Smoking	11 (61)	1 (4)	<0.001†
Previous cardiovascular disease, <i>N</i> (%)			
Acute stroke	3 (17)	2 (7)	0.365†
Transient ischemic attack	2 (11)	1 (4)	0.552†
Ischemic heart disease	7 (39)	2 (7)	0.018†
Atrial fibrillation	0 (0)	0 (0)	–
Valvular heart disease	2 (11)	0 (0)	0.148†

Continuous variables are reported as the mean ± standard deviation (range). All other data are numbers (percentages). Values in boldface are statistically significant.

* *P* value = independent *t*-test; *P* < 0.05 was set for clinical significance.

† *P* value = Fisher's exact test; *P* < 0.05 was set for clinical significance.

acute stroke, transient ischemic attack, atrial fibrillation confirmed by electrocardiogram, and valvular heart disease) in all patients to assess cardio-/cerebrovascular risk factors. We then subcategorized the included patients into two groups based on the initial ophthalmic examination: an embolic BRAO group (patients having indisputable retinal emboli) and a nonembolic BRAO group (patients not having apparent retinal emboli at the time of initial examination).

Brain Magnetic Resonance Images and Carotid Artery Stenosis Evaluation

We assessed the cerebrovascular status of the included patients with BRAO by grading the initial brain MRI data, which was performed with a 1.5 T or 3.0 T system (Intera or Achieva; Philips Medical Systems, Best, The Netherlands; or Signa Horizon; GE Medical Systems, Milwaukee, WI, USA).

TABLE 2. Comparison of Brain Magnetic Resonance Images and Embolic Sources According to Emboli Existence in Patients With Branch Retinal Artery Occlusion (BRAO)

Characteristics	Embolic BRAO (<i>N</i> = 18, 39%)	Nonembolic BRAO (<i>N</i> = 28, 61%)	<i>P</i> Value
Brain MRI, <i>N</i>			
Brain lesions			
Acute cerebral infarction, <i>N</i> (%)	5 (28)	1 (4)	0.017
Cerebral small vessel disease			
WMHs*, <i>N</i> (%)			0.187
Grade 0	4 (22)	15 (54)	
Grade 1	5 (28)	6 (21)	
Grade 2	8 (44)	6 (21)	
Grade 3	1 (6)	1 (4)	
CMB, <i>N</i> (%)	1 (6)	5 (18)	0.380
Silent lacunar infarct, <i>N</i> (%)	4 (22)	5 (18)	0.721
Embolic source			
TFCA or MRA, <i>N</i> (%)	13 (72)	19 (68)	
Carotid artery stenosis†, <i>N</i> (%)			0.028
Absent to mild	2 (15)	11 (58)	
Moderate to severe	11 (85)	8 (42)	
Cardioembolic source, <i>N</i> (%)			
Atrial fibrillation	0 (0)	0 (0)	
Small vessel disease without large vessel pathology, <i>N</i> (%)	1/13 (7)	11/19 (58)	0.008

Continuous variables are reported as the mean ± standard deviation (range). All other data are numbers (percentages). *P* values were calculated by Fisher's exact test; *P* < 0.05 was set for clinical significance. Values in boldface are statistically significant. PVH, periventricular hyperintensity.

* WMHs were graded by Fazekas scale: grade 0, absent; 1, caps or pencil-thin lining; 2, smooth halo; and 3, irregular periventricular signal extending into the deep white matter.

† Carotid artery stenosis was classified by NASCET criteria: mild (<50%), moderate (50–70%), or severe (≥70%).

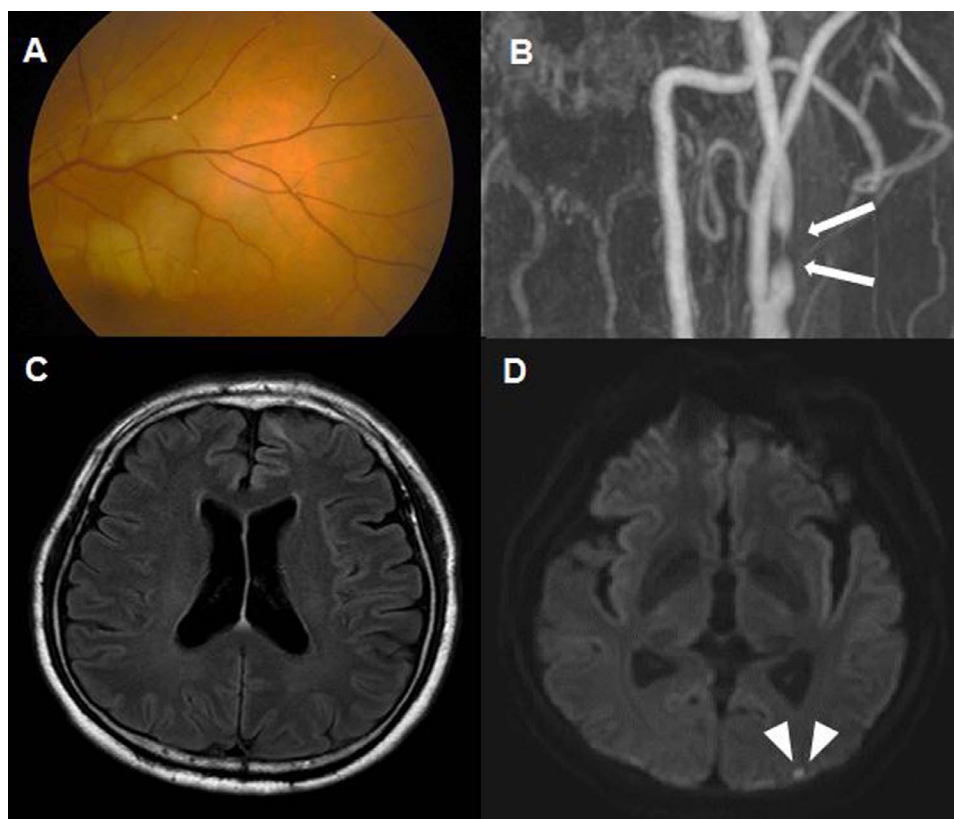


FIGURE 3. (A) A case of branch retinal artery occlusion (BRAO) with multiple visible emboli observed in a branch of the superotemporal retinal artery in a 77-year-old man. (B) Severe stenosis by NASCET criteria at the left proximal internal carotid artery, regarded as the cause of retinal emboli, is shown in the MRA (white arrow). (C) White matter hyperintensities, cerebral microbleeds, or silent lacunar infarct is not visible in brain MRI (FLAIR image), but (D) a concurrent acute infarction in left occipital lobe is shown in a T2-weighted MRI. MRA, magnetic resonance angiography; MRI, magnetic resonance image; FLAIR, fluid-attenuated inversion recovery.

The whole brain was scanned with a slice thickness of 5.0 mm in the axial plane using T1-weighted images [repetition time (TR)/echo time (TE) = 300/10], T2-weighted images (TR/TE = 4800/100), fluid-attenuated inversion recovery images (TR/TE = 11,000/140), T2 fast field echo images (TR/TE = 724/23), diffusion-weighted images (TR/TE = 4800/66), and three-dimensional time of flight MRA images (TR/TE = 20/7, slice thickness = 1.2 mm). Acute cerebral infarcts were defined as focal diffusion-restricted lesions in diffusion-weighted images.⁹ Cerebral SVD is usually divided into WMHs, CMBs, and silent lacunar infarctions (Fig. 2).¹⁷ The Fazekas scale was used to assess WMHs. We classified participants into four severity groups according to their Fazekas score: grade 0 (absent), grade 1 (caps or pencil-thin lining), grade 2 (smooth halo), and grade 3 (irregular periventricular signal extending into the deep white matter).²³ White matter hyperintensities were areas of bright, high-signal intensities noted on T2-weighted images. We defined CMBs as black, round lesions with a blooming effect on gradient echo MRI, devoid of T1-weighted or T2-weighted hyperintensity, with at least half of the lesion surrounded by brain parenchyma between 1 and 5 mm in diameter.^{24,25} Silent lacunar infarction was defined as focal lesions in the deep perforator territory ≥ 3 mm in diameter with a hyperintense signal on T2-weighted images or fluid attenuation inversion recovery images and a hypointense signal on T1-weighted images, often surrounded by a hyperintense signal rim on fluid attenuation inversion recovery images.¹⁸ Based on this classification, we defined cerebral SVD as one of the following; grade 1 or greater WMHs, presence of CMB, or presence of silent lacunar infarction.

We evaluated carotid artery stenosis status by transfemoral catheter angiography (TFCA) or MRA in 28 patients (61%). We graded carotid artery stenosis according to the North American Symptomatic Carotid Endarterectomy Trial (NASCET) criteria as absent, mild (<50%), moderate (50%–70%), or severe ($\geq 70\%$),²⁶ and divided patients with stenosis into two groups of absent to mild or moderate to severe, because a moderate to severe degree of stenosis is a clinically significant or possible cause of emboli formation.

In order to ensure accurate judgments from subjective observations, one trained ophthalmologist (KHC) and one trained stroke neurologist (CKK), both blinded to the clinical information, assessed the degree of WMHs, CMBs, and silent lacunar infarctions on the brain MRI and carotid stenosis status on the TFCA or MRA. Any disagreement was resolved by reevaluation and discussion.

Statistical Analysis

Interobserver agreement for brain MRI and carotid stenosis status evaluation between the two investigators (KHC and CKK) was excellent (Cohen's κ value of 0.801 and 0.871, respectively).²⁷ We used SPSS version 22.0 for Windows (SPSS, Inc., Chicago, IL, USA) for statistical analyses. P values < 0.05 were considered to indicate statistically significant differences. The institutional review board of the Seoul National University, Bundang Hospital approved the study (IRB No: B-1506-304-114), which was conducted in accordance with the Declaration of Helsinki.

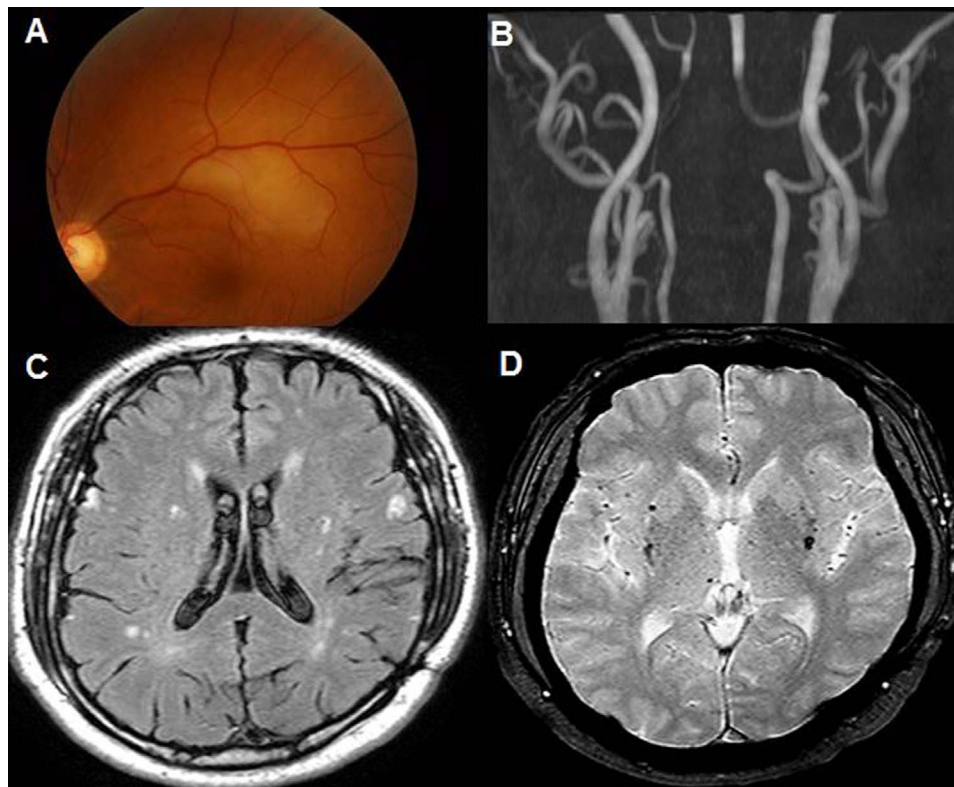


FIGURE 4. (A) A case of branch retinal artery occlusion (BRAO) without visible retinal emboli in fundus photography in an 84-year-old man. (B) Steno-occlusive lesions are not visible in intracranial and neck vessels on MRA. (C, D) White matter hyperintensities (Fazekas grade 2) on brain MRI (FLAIR image) and multiple cerebral microbleeds in both parietal lobes on T2-weighted brain MRI, corresponding to cerebral small vessel disease. MRA, magnetic resonance angiography; MRI, magnetic resonance image; FLAIR, fluid-attenuated inversion recovery.

RESULTS

Demographics and Clinical Characteristics

We included a total of 46 patients with BRAO (35 men and 11 women), comprising 18 in the embolic group and 28 in the nonembolic group. Table 1 presents the demographics, clinical characteristics, and cardiovascular histories. Briefly, the mean age was 64.5 years (range, 18–92 years), and the time from symptom onset to initial diagnosis was 93.2 hours. Hypertension was the most common underlying condition (35 patients, 76%), followed by diabetes mellitus and dyslipidemia. There was no difference between embolic and nonembolic BRAO groups in the prevalence of hypertension, diabetes mellitus, and dyslipidemia; however, patients in the embolic group were more likely to be smokers than those in the nonembolic group ($P < 0.001$). In addition, patients in the embolic group were more likely to have had previous cardiovascular diseases, including acute stroke, transient ischemic attack, ischemic heart disease, and valvular heart disease, than patients in the nonembolic group, although only the difference in ischemic heart disease prevalence had a statistical significance ($P = 0.018$).

Findings of Brain MRI and Carotid Artery Evaluation According to Emboli Existence

Patients in the embolic group had a higher frequency of acute cerebral infarctions, meaning a concurrent ischemic brain infarct, along with a higher frequency of stenotic carotid arteries compared to those in the nonembolic group ($P = 0.017$ and 0.028 , respectively). The overall prevalence of cerebral

SVD did not differ between the embolic and nonembolic groups. One peculiarity of cerebral SVD was that the nonembolic group tended to have a higher prevalence of CMBs and cerebral SVD without large vessel pathology ($P = 0.008$; Table 2). In electrocardiogram monitoring, cardioembolic sources related to atrial fibrillation were not detected in either the embolic or nonembolic group. Figure 3 shows a case of BRAO with multiple cholesterol emboli, with an acute cerebral infarction and cerebral LVD simultaneously with severe carotid artery stenosis without cerebral SVD. Conversely, Figure 4 shows a case of BRAO without visible retinal emboli, with only cerebral SVD and relatively normal carotid artery state on MRA (no larger artery disease pathology).

DISCUSSION

We evaluated fundus photography, brain MRI, and carotid artery status in 46 eyes of 46 patients with BRAO. After categorization of patients with BRAO according to the visibility of emboli on the fundus photography, we observed that the embolic BRAO group tended to have significantly greater smoking history, prevalence of concurrent acute ischemic stroke, and frequency of moderate-to-severe carotid artery stenosis compared to the nonembolic BRAO group. The present results provide the evidence that links LVD etiology and BRAO, as previous studies have suggested.^{5,6} Interestingly, the nonembolic group demonstrated quite different characteristics and underlying conditions compared to the embolic group, suggesting that BRAO might have an additive or additional pathophysiology other than the LVD etiology. This assumption may become more clear when considering that the

nonembolic group also included some patients with emboli at the BRAO incident that had disappeared or moved by the fundus examination.³ As stated previously, the branch retinal artery is an arteriole with the same embryologic background as the brain arterioles, which are the site of cerebral SVD.³ Historically, cerebral SVD has been considered as a group of pathologic processes with various etiologies that affect the small arteries and arterioles of the brain, and that might result in lacunar infarction, vascular dementia, and intracerebral hemorrhage. As these small arteries and arterioles are not easily visualized using conventional brain MRI/MRA, brain MRI findings such as WMHs, CMBs, and radiologic lacunar infarction have been assumed to indicate SVD. Unlike previous studies investigating retinal microvascular changes in patients with cerebral SVD and LVD,^{7,9,11,28} we assessed brain MRIs and carotid artery stenosis in patients with the retinal vascular occlusive disease BRAO. Although the overall proportions of cerebral SVD did not differ significantly according to existence of retinal emboli in patients with BRAO, cerebral SVD without LVD was frequently present in the nonembolic BRAO group. This finding might thus be evidence supporting an SVD etiology in BRAO, especially in patients without clear LVD. With a prevalence of approximately 6%, CMBs are common among healthy elderly individuals.^{16,29} Cerebral microbleeds that share an etiologic basis with intracranial hemorrhage (ICH) are regarded as an indicator of imminent ICH, which is a representative hypertensive microangiopathy; furthermore, they may also indicate inadequately treated hypertension.¹⁵

Our findings provide a framework for understanding the etiology of BRAO, especially in patients who are not at a traditionally increased vascular risk of LVD. Some cases of BRAO might be retinal analogues of SVD lesions observed on brain MRI, and might be at least partially attributed to arteriolosclerosis or amyloid angiopathy, which are thought to be disease mechanisms of SVD. This does not devalue the role of emboli and LVD etiology in BRAO, but rather indicates the importance of not overlooking other mechanisms, including SVD etiology.

Our study had some limitations. First, the number of included patients with BRAO was quite small, although our study was one of the largest regarding BRAO. Second, the time from presentation of the first symptom to the first retinal evaluation varied from 1 hour to 14 days, which might affect the identification of retinal emboli. This is partially due to the wide spectrum of disease severity in patients with BRAO and is an inherent limitation of a retrospective case series. Third, our study lacked a control group to address the confounding factors that might affect brain MRI pathologies and carotid artery stenosis. Moreover, longitudinal follow-up data would be helpful in assessing outcomes of interest, including cardiovascular events, vascular dementia, and cognitive dysfunction. Despite these pitfalls, we believe that the findings of our study could point to an additional explanation for the etiology of BRAO. To our knowledge, this is the first study to suggest the possibility of cerebral SVD as a contributor to the development of BRAO. Further investigations, including a much larger-scaled multi-institutional study and comprehensive analysis of fundus photography and brain images in BRAO and other retinal vascular diseases, are now warranted.

Acknowledgments

Supported by the grant funded by the Seoul National University Bundang Hospital (SNUBH) Research Fund (grant No: 13-2016-016). The sponsor or funding organization had no role in the design or conduct of this research.

Disclosure: **K.H. Cho**, None; **C.K. Kim**, None; **S.J. Woo**, None; **K.H. Park**, None; **S.J. Park**, None

References

- Hayreh SS. Acute retinal arterial occlusive disorders. *Prog Retin Eye Res*. 2011;30:359–394.
- Cho KH, Ahn SJ, Jung C, Han MK, Park KH, Woo SJ. Ischemic injury of the papillomacular bundle is a predictive marker of poor vision in eyes with branch retinal artery occlusion. *Am J Ophthalmol*. 2016;162:107–120.
- Hayreh SS, Zimmerman MB. Fundus changes in branch retinal arteriolar occlusion. *Retina*. 2015;35:2060–2066.
- Park SJ, Choi NK, Seo KH, Park KH, Woo SJ. Nationwide incidence of clinically diagnosed central retinal artery occlusion in Korea 2008 to 2011. *Ophthalmology*. 2014;121:1933–1938.
- Brown GC, Shields JA. Cilioretinal arteries and retinal arterial occlusion. *Arch Ophthalmol*. 1979;97:84–92.
- Hayreh SS, Podhajsky PA, Zimmerman MB. Retinal artery occlusion: associated systemic and ophthalmic abnormalities. *Ophthalmology*. 2009;116:1928–1936.
- Baker ML, Hand PJ, Liew G, et al. Retinal microvascular signs may provide clues to the underlying vasculopathy in patients with deep intracerebral hemorrhage. *Stroke*. 2010;41:618–623.
- Cheung CY, Chen C, Wong TY. Ocular fundus photography as a tool to study stroke and dementia. *Semin Neurol*. 2015;35:481–490.
- De Silva DA, Manzano JJ, Woon FP, et al. Associations of retinal microvascular signs and intracranial large artery disease. *Stroke*. 2011;42:812–814.
- Qiu C, Cotch MF, Sigurdsson S, et al. Microvascular lesions in the brain and retina: the age gene/environment susceptibility-Reykjavik study. *Ann Neurol*. 2009;65:569–576.
- Yatsuya H, Folsom AR, Wong TY, Klein R, Klein BE, Sharrett AR. Retinal microvascular abnormalities and risk of lacunar stroke: Atherosclerosis Risk in Communities Study. *Stroke*. 2010;41:1349–1355.
- Jacobs N. Concerning central retinal artery occlusion (CRAO) and cerebral stroke. *Eye*. 2014;28:1269–1270.
- Lee J, Kim SW, Lee SC, Kwon OW, Kim YD, Byeon SH. Co-occurrence of acute retinal artery occlusion and acute ischemic stroke: diffusion-weighted magnetic resonance imaging study. *Am J Ophthalmol*. 2014;157:1231–1238.
- Park SJ, Choi NK, Yang BR, et al. Risk and risk periods for stroke and acute myocardial infarction in patients with central retinal artery occlusion. *Ophthalmology*. 2015;122:2336–2343.e2.
- Koennecke HC. Cerebral microbleeds on MRI: prevalence, associations and potential clinical implications. *Neurology*. 2006;66:165–171.
- Jeerakathil T, Wolf PA, Beiser A, et al. Cerebral microbleeds: prevalence and associations with cardiovascular risk factors in the Framingham Study. *Stroke*. 2004;35:1831–1835.
- Pantoni L. Cerebral small vessel disease: from pathogenesis and clinical characteristics to therapeutic challenges. *Lancet Neurol*. 2010;9:689–701.
- Sacco S, Marini C, Totaro R, Russo T, Cerone D, Carolei A. A population-based study of the incidence and prognosis of lacunar stroke. *Neurology*. 2006;66:1335–1338.
- Cai Z, Wang C, He W, et al. Cerebral small vessel disease and Alzheimer's disease. *Clin Interv Aging*. 2015;10:1695–1704.
- Conijn MM, Kloppenborg RP, Algra A, et al. Cerebral small vessel disease and risk of death, ischemic stroke and cardiac complications in patients with atherosclerotic disease: the Second Manifestations of ARterial disease-Magnetic Resonance (SMART-MR) study. *Stroke*. 2011;42:3105–3109.

21. Ostergaard L, Engedal TS, Moreton F, et al. Cerebral small vessel disease: capillary pathways to stroke and cognitive decline. *J Cereb Blood Flow Metab.* 2016;36:302–325.
22. Kwon HM, Lynn MJ, Turan TN, et al. Frequency, risk factors and outcome of coexistent small vessel disease and intracranial arterial stenosis: results from the Stenting and Aggressive Medical Management for Preventing Recurrent Stroke in Intracranial Stenosis (SAMMPRIS) trial. *JAMA Neurol.* 2016;73:36–42.
23. Fazekas F, Chawluk JB, Alavi A, Hurtig HI, Zimmerman RA. MR signal abnormalities at 1.5 T in Alzheimer's dementia and normal aging. *Am J Roentgenol.* 1987;149:351–356.
24. Cordonnier C, Al-Shahi Salman R, Wardlaw J. Spontaneous brain microbleeds: systematic review, subgroup analyses and standards for study design and reporting. *Brain.* 2007;130:1988–2003.
25. Braun H, Schreiber S. Microbleeds in cerebral small vessel disease. *Lancet Neurol.* 2013;12:735–736.
26. Bash S, Villablanca JP, Jahan R, et al. Intracranial vascular stenosis and occlusive disease: evaluation with CT angiography, MR angiography, and digital subtraction angiography. *Am J Neuroradiol.* 2005;26:1012–1021.
27. Landis JR, Koch GG. The measurement of observer agreement for categorical data. *Biometrics.* 1977;33:159–174.
28. Lindley RI, Wang JJ, Wong MC, et al. Retinal microvasculature in acute lacunar stroke: a cross-sectional study. *Lancet Neurol.* 2009;8:628–634.
29. Roob G, Schmidt R, Kapeller P, Lechner A, Hartung HP, Fazekas F. MRI evidence of past cerebral microbleeds in a healthy elderly population. *Neurology.* 1999;52:991–994.