

Retinal Vein Occlusion as the Surrogate Marker for Premature Brain Aging in Young Patients

Kwan Hyuk Cho,^{1,2} Chi Kyung Kim,³ Kyungmi Oh,³ Seung-Won Oh,⁴ Kyu Hyung Park,¹ and Sang Jun Park¹

¹Department of Ophthalmology, Seoul National University College of Medicine, Seoul National University Bundang Hospital, Seongnam, Republic of Korea

²HanGil Eye Hospital, Incheon, Republic of Korea

³Department of Neurology, Korea University Guro Hospital and Korea University College of Medicine, Seoul, Republic of Korea

⁴Department of Family Medicine, Healthcare System Gangnam Center, Seoul National University Hospital, Seoul, Republic of Korea

Correspondence: Sang Jun Park, Department of Ophthalmology, Seoul National University Bundang Hospital, 82, Gumiro 173 beon-gil, Bundang-gu, Seongnam, 13620, Republic of Korea; sangjunpark@snu.ac.kr.

KHC and CKK contributed equally to the work presented here and should therefore be regarded as equivalent authors.

Submitted: January 1, 2017

Accepted: April 15, 2017

Citation: Cho KH, Kim CK, Oh K, Oh S-W, Park KH, Park SJ. Retinal vein occlusion as the surrogate marker for premature brain aging in young patients. *Invest Ophthalmol Vis Sci*. 2017;58:BIO82-BIO87. DOI:10.1167/iov.17-21413

PURPOSE. We investigated cerebral small vessel disease (SVD) in patients with incidental retinal vein occlusion (RVO).

METHODS. This retrospective, case-control, observational trial included 125 patients with RVO who underwent brain magnetic resonance imaging (MRI) and 1105 age-matched controls who underwent comprehensive medical interviews and MRI. Underlying cardiovascular diseases and MRI findings were investigated in the patients with RVO according to age (<60 or ≥60 years) and RVO occlusion level (central or branch). The characteristics of underlying cardiovascular disease and MRI findings were compared between the younger patients with RVO and age-matched controls. The cerebrovascular burden also was assessed in the younger patients with RVO.

RESULTS. The mean age of the patients with RVO was 63.9 ± 12.1 years and the predominant underlying disease was hypertension (72/125, 58%). The older RVO group had a longer history of hypertension and less smoking history. The prevalence of cerebral SVD in the RVO group was 54% (68/125), and was significantly higher in older than in younger patients with RVO (62% [53/86] vs. 38% [15/39], $P = 0.016$). However, the latter had a significantly higher prevalence of cerebral SVD than their age-matched controls (38% [15/39] vs. 4% [47/1105], $P < 0.001$). There was no difference in prevalence of cerebral SVD between the central and branch RVO groups ($P = 0.478$).

CONCLUSIONS. Cerebral SVD presented frequently in patients with RVO and was magnified in young patients, suggesting that RVO is a surrogate marker for cerebral SVD.

Keywords: retinal vein occlusion, cerebral small vessel disease, brain MRI

Retinal vein occlusion (RVO) is the second most common retinal vascular disease causing vision loss and affects approximately 16 million people worldwide.^{1,2} In population-based studies, the incidence of RVO is greater than 48 per 100,000 person-years in the general population, and is higher in those aged 50 years or older. The incidence of RVO has increased exponentially with the increasing age of the population, and the health-related burden of the disease also has expanded. However, the incidence of RVO also is considerable in the younger population.^{3,4} Emerging evidence suggests that RVO is associated with subsequent cardiovascular disease, including stroke and myocardial infarction, and that hypertension, diabetes mellitus, hyperlipidemia, and cigarette smoking are risk factors.^{2,4-8} RVO-related hemodynamic changes and thrombus formation result from compression of an adjacent retinal vein by a thickened retinal artery, that is, anatomically classified as a small artery to arteriole. Therefore, RVO is considered to be an arterial disease.^{3,4,9} Although its layered anatomy and metabolic activity are a little different from those of the brain, the retina differentiates from the diencephalon during embryonic development, so it shares some physiologic characteristics with the brain.¹⁰⁻¹⁵ Interestingly,

similar pathologic changes that occur with RVO also are manifested in the brain in the form of cerebral small vessel disease (SVD), including white matter hyperintensities (WMH), cerebral microbleeds (CMBs), and silent lacunar infarcts. In this study, we investigated the little known association between RVO and cerebral SVD using magnetic resonance imaging (MRI) of the brain and fundus photography.

METHODS

The study was approved by the institutional review boards at Seoul National University Bundang Hospital (approval number B-1506-304-114) and Seoul National University Hospital (SNUH) Healthcare System Gangnam Center (approval number J-1609-065-791), and was conducted in accordance with the tenets of the Declaration of Helsinki.

We searched the RVO registry database at Seoul National University Bundang Hospital and identified 524 consecutive patients with an incidental finding of RVO (137 with central and 387 with branch RVO) between January 2009 and October 2014. Patients who had RVO combined with retinal artery



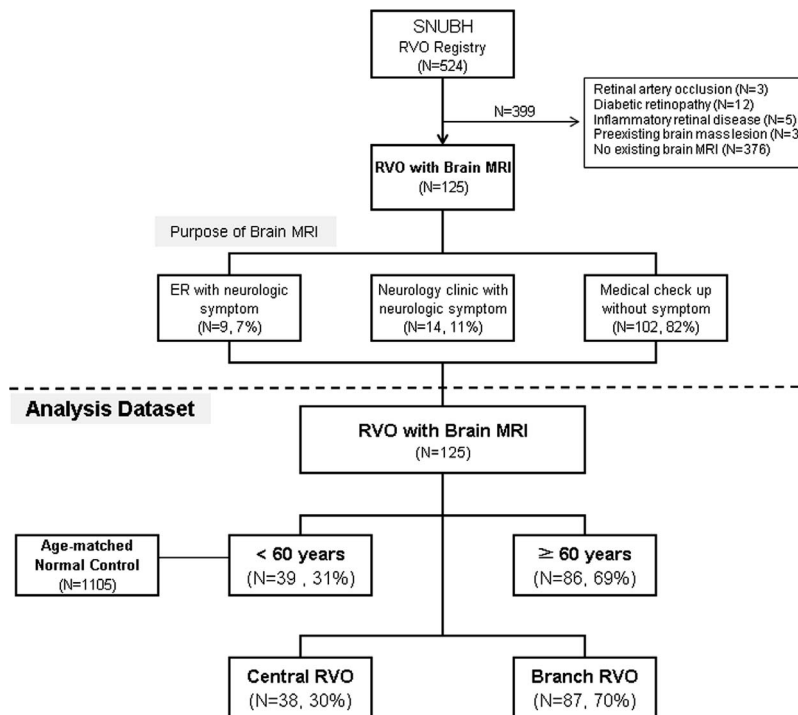


FIGURE 1. Flow diagram showing the selection and subgrouping for the enrolled eyes with RVO. The age-matched controls were individuals who had attended SNUH Healthcare System Gangnam Center for routine health screening. ER, emergency room.

occlusion ($n = 3$), diabetic retinopathy ($n = 12$), inflammatory retinal disease ($n = 5$), or a pre-existing brain mass lesion ($n = 3$) were excluded. No patient had other serious ocular disease or a hematologic or inflammatory etiology for RVO. We identified the patients who also had undergone brain MRI within 1 year on either side of the first presentation of incidental RVO. We also investigated the reason for brain MRI in these patients; brain MRI sometimes was ordered by the neurologists, but was performed mostly in the absence of neurologic symptoms as part of a health screening program. A total of 125 patients with incidental RVO and results for MRI of the brain could be included in the analysis. Figure 1 shows a flow chart of the subject selection process and final dataset available for analysis.

Demographics, Medical History, and Ophthalmic Evaluation

All patients underwent a complete ophthalmic examination at the initial visit, which included slit-lamp biomicroscopy, indirect ophthalmoscopy, fundus photography (Vx-10; Kowa Optimed, Tokyo, Japan; Optos PLC, Dunfermline, Scotland, UK), and fluorescein angiography (Vx-10, Kowa Optimed). We obtained demographic information and a medical history (e.g., hypertension, diabetes mellitus, dyslipidemia, smoking, and cardiovascular disease, including acute stroke, transient ischemic attack, atrial fibrillation, and valvular heart disease) by detailed review of all patients' medical charts to evaluate cardiovascular risk factors. We also reviewed laboratory test results (e.g., complete blood cell count, erythrocyte sedimentation rate, C-reactive protein, and blood coagulation test) in all patients to identify a specific cause for RVO. We then subcategorized the patients according to age (< 60 or ≥ 60 years). The prevalence of cerebral SVD is different between older and younger age groups. Several well-known population-based studies of cerebral SVD selected 60 years as a cutoff

value for the elderly population. Accordingly, we chose 60 years as the cutoff value for our analysis of the relationship between RVO and cerebral SVD.^{16–18} Further, we subcategorized the patients according to level of RVO (central or branch) and analyzed central RVO (CRVO) according to area of capillary nonperfusion (10 disc diopters on fluorescein angiography, ischemic or nonischemic) based on initial ophthalmic examination.

Age-Matched Controls for Young Patients With RVO

Age is a potent risk factor of cerebral SVD, and age-matched controls for old patients with RVO do not have clinical significance. To compare brain MRI findings between younger patients with RVO and the normal population, we retrospectively reviewed a consecutive series of 1110 neurologically healthy individuals (< 60 years) who visited SNUH Healthcare System Gangnam Center for a routine health check between October 2003 and December 2004, and participated in the SNUH Gangnam Survey.^{19,20} We defined neurologically and ophthalmologically healthy individuals as those who had not experienced a stroke or transient ischemic attack, had no symptoms or signs of neurologic disease, had no decrease in best corrected visual acuity, and had no history of retinal disease. Five of these 1110 individuals had not undergone a brain MRI, so they were excluded, leaving 1105 asymptomatic individuals with brain MRI results and without overt neurologic or retinal disease for enrolment. Clinical information was obtained by personal interview, and each subject underwent a physical examination by a trained physician.

Evaluation of Brain MRI

We evaluated aging of the brain and the status of the vessels in patients with RVO using a 1.5 or 3.0 Tesla MRI scanner (Intera

TABLE 1. Clinical Characteristics and Underlying Diseases in Patients With RVO

Characteristics	All RVO, <i>n</i> = 125, 100%	<60 y, <i>n</i> = 39, 31%	≥60 y, <i>n</i> = 86, 69%	<i>P</i> Value
Age, mean, y	63.9 ± 12.1	50.5 ± 9.4	70.2 ± 6.9	0.001*†
Sex, male, <i>n</i> (%)	57 (46%)	25 (64%)	32 (37%)	0.005*‡
Past medical history, <i>n</i> (%)				
Hypertension	72 (58%)	18 (46%)	54 (63%)	0.061‡
Diabetes	28 (22%)	6 (15%)	22 (26%)	0.205‡
Dyslipidemia	50 (40%)	12 (31%)	38 (44%)	0.156‡
Smoking	26 (21%)	15 (38%)	11 (13%)	0.001*‡
Previous cardiovascular disease, <i>n</i> (%)				
Acute stroke	33 (26%)	8 (21%)	25 (29%)	0.315‡
Transient ischemic attack	6 (5%)	1 (3%)	5 (6%)	0.390‡
Ischemic heart disease	28 (22%)	6 (15%)	22 (26%)	0.205‡
Atrial fibrillation	6 (5%)	1 (3%)	5 (6%)	0.390‡
Valvular heart disease	8 (6%)	2 (5%)	6 (7%)	0.892‡

The data are reported as numbers (percentages). All *P* values are for comparisons between subjects aged <60 and ≥60 years.

* *P* < 0.05.

† Mann-Whitney *U* test.

‡ Fisher's exact test.

or Achieva; Philips, Best, The Netherlands; Signa; GE, Milwaukee, WI, USA). The 5 mm axial slices were obtained using conventional MR protocols: T1-weighted (repetition time [TR]/echo time [TE], 300/12), T2-weighted (TR/TE, 4800/100), and fluid attenuated inversion recovery (FLAIR) (TR/TE, 11,000/140) images. An additional special protocol, that is T2* gradient-recalled echo (GRE) images (TR/TE, 724/23), was used to assess CMBs, one of the MRI markers for SVD in the brain, and diffusion-weighted MRI (TR/TE, 4800/66) was performed to evaluate acute infarction. The large vessels of the brain were visualized on time-of-flight angiographic images with three-dimensional reconstruction on MRI (TR/TE, 20/7; thickness, 1.2 mm). WMHs, CMBs, silent lacunar infarctions composed of cerebral SVD, and acute cerebral infarcts were defined as focal high-signal lesions on diffusion-weighted MR images.^{13,21} WMHs were graded by the Fazekas score (0, absent; 1, caps and thin lining in the ventricle or scattered dot lesions in white matter; 2, smooth halo or early confluent lesions in deep white matter; 3, massive periventricular lesions extending to the deep white matter with a confluent shape).²² CMBs were defined as round-shaped dark signals with a blooming artifact on T2*-GRE images and within 5 mm in diameter.^{23,24} Silent lacunar infarction was detected as a hyperintense signal on T2-weighted or FLAIR images and hypointensity on T2-weighted images with a diameter between 3 mm and 2 cm.²⁵ As described in our previous study, cerebral SVD was deemed to be present if the brain had one of the following markers: a Fazekas score of 1 or more on WMHs, existence of CMB, or presence of silent lacunar infarction.²⁶ MR images for the control group were captured using a 1.5 Tesla Chorus MRI scanner (ISOL Technology, Inc., Kyungki-Do, Republic of Korea). No subject in this study had experienced acute ischemic stroke, so routine protocols were used in this survey except for the diffusion-weighted images. T1-weighted (TR/TE = 520/12), T2-weighted (TR/TE = 5800/96), FLAIR (TR/TE = 8500/96; inversion time = 2100), and T2*-GRE (TR/TE = 150/15; flip angle, 26°) images were obtained. One set of images comprised 24 transaxial slices per scan without an interslice gap.

To ensure accurate judgments from subjective observations, one trained ophthalmologist (KHC) and one trained stroke neurologist (CKK), both blinded to the clinical information, assessed the degree of WMH, CMBs, and silent lacunar infarctions on brain MRI. Any disagreement was resolved by re-evaluation and discussion.

Statistical Analysis

Interobserver agreement for brain MRI between the two investigators (KHC, CKK) was excellent (Cohen's κ = 0.845).²⁷ The statistical analysis was performed using SPSS version 22.0 for Windows (IBM Corp., Armonk, NY, USA). *P* values < 0.05 were considered to be statistically significant.

RESULTS

Demographic and Clinical Characteristics

We included a total of 125 patients with RVO (57 men, 68 women), comprising 38 in the central RVO group and 87 in the branch RVO group. The mean age was 63.9 (range, 20–89 years) and 86 patients were older than 60 years at the time of their initial diagnosis. Hypertension was the most common underlying condition (72 patients, 58%), followed by dyslipidemia and diabetes mellitus. There was no difference in the prevalence of diabetes mellitus and dyslipidemia between the groups when categorized by age; however, patients younger than 60 years were more likely to smoke (*P* = 0.001) and less likely to have hypertension (*P* = 0.061) than their older counterparts. In addition, patients showed a similar incidence of previous cardiovascular diseases, including acute stroke, transient ischemic attack, ischemic heart disease, and valvular heart disease in the groups of age categorization (Table 1).

Brain MRI Findings According to Age in Patients With RVO

We evaluated the reasons for brain MRI in all subjects. Nine patients (7%) visited the emergency room with neurologic symptoms, 14 (11%) visited the outpatient clinic in our neurology department with neurologic symptoms, and the others (82%) underwent brain MRI in the absence of neurologic symptoms as part of a comprehensive health screening program. Therefore, most information was gathered incidentally. The overall prevalence rates of acute cerebral infarction (concurrent ischemic brain infarct) and cerebral SVD in the patients with RVO were 5% and 54%, respectively. Patients with RVO who were aged 60 years or older showed a similar prevalence of acute cerebral infarction (*P* = 0.375), but their prevalence of cerebral SVD was significantly higher than that in patients younger than 60 years (62% [*n* = 53] vs. 38% [*n*

TABLE 2. Comparison of Brain MRI According to Age in Patients With RVO

Brain Lesions	All RVO, <i>n</i> = 125, 100%	<60 y, <i>n</i> = 39, 31%	≥60 y, <i>n</i> = 86, 69%	<i>P</i> Value
Acute cerebral infarction, <i>n</i> (%)	6 (5%)	3 (8%)	3 (3%)	0.375
Cerebral SVD	68 (54%)	15 (38%)	53 (62%)	0.016*
WMH, <i>n</i> (%)†				
Grade 0	32 (26%)	17 (44%)	15 (17%)	0.002*
Grade 1	34 (27%)	15 (38%)	19 (22%)	0.057
Grade 2	38 (30%)	12 (31%)	26 (30%)	0.373
Grade 3	18 (14%)	1 (3%)	17 (20%)	0.007*
CMB, <i>n</i> (%)	13 (10%)	5 (13%)	8 (9%)	0.379
Silent lacunar infarct, <i>n</i> (%)	35 (28%)	9 (23%)	26 (30%)	0.409

Continuous variables are reported as the mean \pm SD. All other data are reported as numbers (percentages). All *P* values are for comparisons between subjects aged <60 and \geq 60 years.

* $P < 0.05$.

† Fisher's exact test.

= 15], $P = 0.016$). Although the patients over 60 years old had significantly more grade 3 WMH ($P = 0.007$), CMBs and silent lacunar infarcts did not differ according to age category ($P = 0.379$ and $P = 0.409$, respectively; Table 2; Fig. 2).

The younger patients with RVO (mean age, 50.5 ± 9.4 years) had cardiovascular risk factors similar to those in the control group. However, the younger patients with RVO had a significantly higher overall prevalence of SVD ($P \leq 0.001$), including significantly higher prevalence rates of WMH, CMBs, and silent lacunar infarcts (all $P < 0.05$; Table 3; Fig. 3).

Brain MRI Findings According to Anatomy in Patients With RVO

The frequencies of acute cerebral infarction and cerebral SVD were similar between the central and branch RVO groups ($P = 0.873$ and $P = 0.654$, respectively). Further, the distribution of subtypes of cerebral SVD, including WMH, CMB, and silent lacunar infarct, was not significantly different between the two groups (Supplementary Table S1). In addition, prevalence or distribution of subtypes of cerebral SVD was not significantly different between ischemic and nonischemic CRVO (Supplementary Table S2).

DISCUSSION

We evaluated fundus photography, fluorescein angiography, and brain MRI results in 125 patients with incidental RVO, and compared the findings of these investigations in young patients with RVO aged <60 years to those in an age-matched control population. Although concurrent stroke was relatively common (6 of 125 patients, 5%), more than half of the patients with incidental RVO presented with cerebral SVD, which increases the risk of future cognitive impairment, ischemic stroke, and even vascular death irrespective of cardiovascular disease.^{28–32} In addition, when focusing on the younger patients with RVO, the burden of cerebral SVD was considerably large compared to that in the age-matched normal population.

Historically, cerebral SVD has been considered as a group of pathologic processes with various etiologies that affect the small arteries and arterioles of the brain.^{21,23} The retinal artery, blockage of which is assumed to be the fundamental cause of RVO, is a small artery to arteriole level vessel with the same embryologic origin as the brain arterioles.^{12,14,33,34} Because of this anatomic and embryologic relationship, cerebral SVD was found frequently in patients with RVO in the present study, and this was not surprising.

Cerebral SVD is known to be a marker of vascular ageing and accumulation of vascular risks, and the importance of early modification of risk factors, particularly hypertension, in patients with cerebral SVD currently is emerging.^{21,28,31,35} RVO also is known to be a vascular disease with similar vascular risks.^{4,36} Accordingly, the same disease developing in separate organs could indicate a shared disease mechanism and similar underlying risk factors for the disease. However, we must look at this problem from different angles when considering our results in young patients with RVO. When we compared our young patients with RVO with an age-matched normal population with similar vascular risk factors, we found a large burden of cerebral SVD in the RVO group. This finding indicates that the relationship between RVO and SVD is not only as a marker of accumulated risk for vascular disease, but also a crucial indicator of vascular aging in individual patients. An ophthalmologic finding of RVO, especially at a relatively young age, could be an indicator of degeneration of brain vessels reflecting cerebrovascular age and not just chronologic age.^{14,30,35}

Several recently published population-based and clinical studies have shown a relationship between retinal vascular disease and acute cerebral stroke, and suggested a higher risk of stroke in young patients with RVO.^{4,29} Another report has proposed that cerebral aging seems accelerated by 10 to 20 years in young patients with stroke.³⁰ Furthermore, several studies have reported that cerebral SVD is associated with cognitive dysfunction and cerebrovascular accident.^{28,31,35,37} Although more data are needed to confirm if this is the case, when these reports are combined with our present results, it seems that RVO and cerebral SVD have a relationship with each other, and this relationship is intensified in young patients. We suggest that identification and treatment of RVO could be a gatekeeper to prevent future cognitive dysfunction and severe neurologic deficit in young patients. Given that RVO usually presents as acute vision loss that may prompt a clinic visit, the primary physician or ophthalmologist must counsel or refer for appropriate evaluation and risk modification.

There are some limitations to our study. First, we included only those patients with RVO whose brain MRI findings were available, which might be a source of selection bias. However, most brain MRI scans were incidentally performed in patients with RVO, which would minimize the likelihood of such bias. Second, there are no long-term follow-up data on the study patients, so we were not able to determine the incidence of SVD in patients with RVO. Unfortunately, we could not investigate the genetic background of patients with cerebral SVD and RVO in this study. Further evaluation is warranted in this respect. In conclusion, patients with RVO have a large

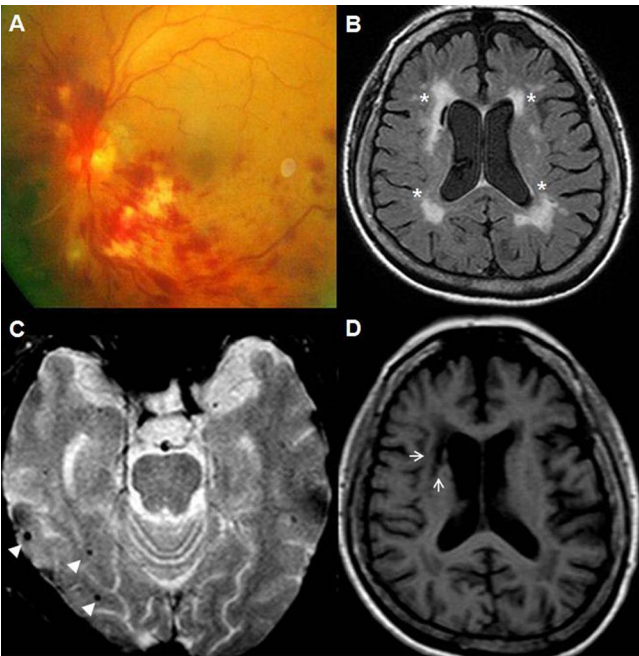


FIGURE 2. Cerebral small vessel disease in old patient with RVO. (A) A case of central RVO with flame-shaped retinal hemorrhage in a 78-year-old woman. (B) White matter hyperintensities (Fazekas grade 3) on brain MRI (FLAIR image; *white asterisks*), (C) multiple cerebral microbleeds on T2-weighted brain MRI (*white arrowhead*), and (D) silent lacunar infarct on T1-weighted MRI (*white arrow*) corresponding to cerebral small vessel disease.

TABLE 3. Comparison of Brain MRI Between Patients Younger Than 60 years Patients and a Control Group

Characteristics	< 60 Years, n = 39	Controls, n = 1105	P Value
Age, mean, y	50.5 ± 9.4	48.3 ± 7.7	0.486†
Sex, male, n (%)	25 (64%)	649 (59%)	0.502
Cardiovascular risk factors, n (%)			
Hypertension	18 (46%)	476 (43%)	0.703
Diabetes	6 (15%)	93 (8%)	0.128
Dyslipidemia	12 (31%)	441 (40%)	0.251
Smoking	15 (38%)	463 (42%)	0.668
Cerebral SVD	15 (38%)	47 (4%)	<0.001*
WMH, n (%)†			
Grade 0	17 (44%)	973 (88%)	<0.001*
Grade 1	15 (38%)	130 (12%)	<0.001*
Grade 2	12 (31%)	2 (0%)	<0.001*
Grade 3	1 (3%)	0 (0%)	0.034*
CMB, n (%)	5 (13%)	38 (3%)	0.002*
Silent lacunar infarct, n (%)	9 (23%)	34 (3%)	<0.001*

WMH were graded on the Fazekas scale: grade 0, absent; 1, caps or pencil-thin lining; 2, smooth halo; or 3, irregular periventricular signal extending into the deep white matter. Continuous variables are reported as the mean ± SD. All other data are reported as numbers (percentages). PVH, periventricular hyperintensity; WMH, white matter hyperintensities.

* $P < 0.05$, statistically significant.

† Mann-Whitney U test, other variables were calculated by Fisher's exact test.

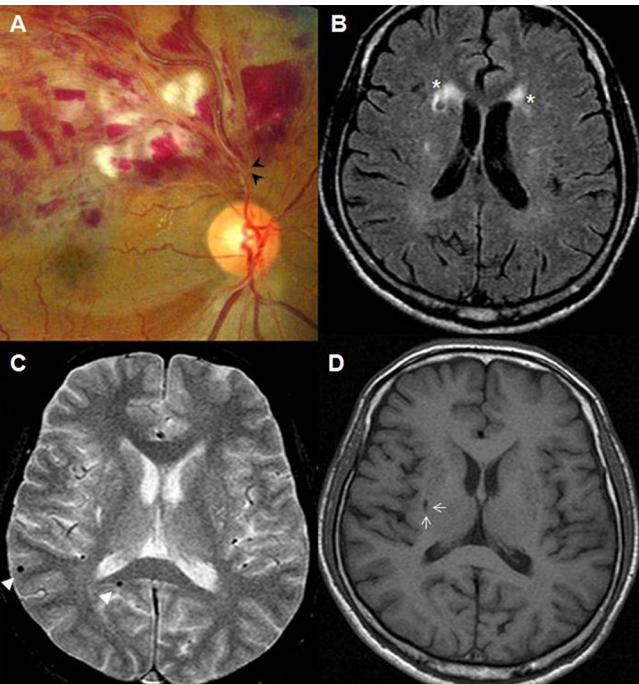


FIGURE 3. Cerebral small vessel disease in young patient with RVO. (A) Branch RVO with flame-shaped retinal hemorrhage and cotton wool spot in a 56-year-old man. Arteriovenous nicking is shown in the proximal portion of the retinal hemorrhage (*black arrowhead*). (B) White matter hyperintensities (Fazekas grade 2) on brain MRI (FLAIR image; *white asterisks*). (C) Multiple cerebral microbleeds on T2-weighted brain MRI (*white arrowhead*). (D) Silent lacunar infarct in a T1-weighted MRI (*white arrow*) corresponding to cerebral small vessel disease.

burden of cerebral SVD, which is magnified in younger patients. We believe that RVO might be a surrogate marker for SVD, especially in the young age groups. Given that young patients with SVD and RVO could be at future risk of severe cerebrovascular disease and cognitive dysfunction, early modification of vascular risk factors may be needed.

Acknowledgments

Supported by the Small Grant for Exploratory Research (SGER) of the National Research Foundation of Korea (NRF), which is funded by the Ministry of Science, ICT, and Future Planning (NRF-2015R1D1A1A02062194). The funding organizations had no role in the design or conduct of this research.

Disclosure: **K.H. Cho**, None; **C.K. Kim**, None; **K. Oh**, None; **S.-W. Oh**, None; **K.H. Park**, None; **S.J. Park**, None

References

1. Hayreh SS. Prevalent misconceptions about acute retinal vascular occlusive disorders. *Prog Retin Eye Res.* 2005;24: 493–519.
2. Rogers S, McIntosh RL, Cheung N, et al. The prevalence of retinal vein occlusion: pooled data from population studies from the United States, Europe, Asia, and Australia. *Ophthalmology.* 2010;117:313–319.e1.
3. Park SJ, Choi NK, Park KH, Woo SJ. Nationwide incidence of clinically diagnosed retinal vein occlusion in Korea, 2008 through 2011: preponderance of women and the impact of aging. *Ophthalmology.* 2014;121:1274–1280.
4. Park SJ, Choi NK, Yang BR, Park KH, Woo SJ. Risk of stroke in retinal vein occlusion. *Neurology.* 2015;85:1578–1584.

5. Hayreh SS, Zimmerman B, McCarthy MJ, Podhajsky P. Systemic diseases associated with various types of retinal vein occlusion. *Am J Ophthalmol*. 2001;131:61-77.
6. Vaccarino V, Badimon L, Corti R, et al. Ischaemic heart disease in women: are there sex differences in pathophysiology and risk factors? Position paper from the working group on coronary pathophysiology and microcirculation of the European Society of Cardiology. *Cardiovasc Res*. 2011;90:9-17.
7. Klein R, Klein BE, Moss SE, Meuer SM. The epidemiology of retinal vein occlusion: the Beaver Dam Eye Study. *Trans Am Ophthalmol Soc*. 2000;98:133-141; discussion 141-133.
8. Wong TY, Larsen EK, Klein R, et al. Cardiovascular risk factors for retinal vein occlusion and arteriolar emboli: the Atherosclerosis Risk in Communities & Cardiovascular Health studies. *Ophthalmology*. 2005;112:540-547.
9. Bertelsen M, Linneberg A, Rosenberg T, et al. Comorbidity in patients with branch retinal vein occlusion: case-control study. *BMJ*. 2012;345:e7885.
10. Lindley RI, Wang JJ, Wong MC, et al. Retinal microvasculature in acute lacunar stroke: a cross-sectional study. *Lancet Neurol*. 2009;8:628-634.
11. Qiu C, Cotch MF, Sigurdsson S, et al. Microvascular lesions in the brain and retina: the age, gene/environment susceptibility-Reykjavik study. *Ann Neurol*. 2009;65:569-576.
12. Baker ML, Hand PJ, Liew G, et al. Retinal microvascular signs may provide clues to the underlying vasculopathy in patients with deep intracerebral hemorrhage. *Stroke*. 2010;41:618-623.
13. De Silva DA, Manzano JJ, Woon FP, et al. Associations of retinal microvascular signs and intracranial large artery disease. *Stroke*. 2011;42:812-814.
14. London A, Benhar I, Schwartz M. The retina as a window to the brain-from eye research to CNS disorders. *Nat Rev Neurol*. 2013;9:44-53.
15. Cheung CY, Chen C, Wong TY. Ocular fundus photography as a tool to study stroke and dementia. *Semin Neurol*. 2015;35:481-490.
16. Del Brutto VJ, Zambrano M, Mera RM, Del Brutto OH. Population-based study of cerebral microbleeds in stroke-free older adults living in rural Ecuador: the Atahualpa Project. *Stroke*. 2015;46:1984-1986.
17. Fukuda K, Takashima Y, Hashimoto M, Uchino A, Yuzuriha T, Yao H. Early menopause and the risk of silent brain infarction in community-dwelling elderly subjects: the Sefuri brain MRI study. *J Stroke Cerebrovasc Dis*. 2014;23:817-822.
18. van Dijk EJ, Prins ND, Vrooman HA, Hofman A, Koudstaal PJ, Breteler MM. Progression of cerebral small vessel disease in relation to risk factors and cognitive consequences: Rotterdam Scan study. *Stroke*. 2008;39:2712-2719.
19. Kwon HM, Kim BJ, Lee SH, Choi SH, Oh BH, Yoon BW. Metabolic syndrome as an independent risk factor of silent brain infarction in healthy people. *Stroke*. 2006;37:466-470.
20. Kim CK, Lee SH, Kim BJ, et al. Elevated leukocyte count in asymptomatic subjects is associated with a higher risk for cerebral white matter lesions. *Clin Neurol Neurosurg*. 2011;113:177-180.
21. Pantoni L. Cerebral small vessel disease: from pathogenesis and clinical characteristics to therapeutic challenges. *Lancet Neurol*. 2010;9:689-701.
22. Fazekas F, Chawluk JB, Alavi A, Hurtig HI, Zimmerman RA. MR signal abnormalities at 1.5 T in Alzheimer's dementia and normal aging. *AJR Am J Roentgenol*. 1987;149:351-356.
23. Braun H, Schreiber S. Microbleeds in cerebral small vessel disease. *Lancet Neurol*. 2013;12:735-736.
24. Cordonnier C, Al-Shahi Salman R, Wardlaw J. Spontaneous brain microbleeds: systematic review, subgroup analyses and standards for study design and reporting. *Brain*. 2007;130:1988-2003.
25. Sacco S, Marini C, Totaro R, Russo T, Cerone D, Carolei A. A population-based study of the incidence and prognosis of lacunar stroke. *Neurology*. 2006;66:1335-1338.
26. Cho KH, Kim CK, Woo SJ, Park KH, Park SJ. Cerebral small vessel disease in branch retinal artery occlusion. *Invest Ophthalmol Vis Sci*. 2016;57:5818-5824.
27. Landis JR, Koch GG. The measurement of observer agreement for categorical data. *Biometrics*. 1977;33:159-174.
28. Conijn MM, Kloppenborg RP, Algra A, et al. Cerebral small vessel disease and risk of death, ischemic stroke, and cardiac complications in patients with atherosclerotic disease: the Second Manifestations of ARterial disease-Magnetic Resonance (SMART-MR) study. *Stroke*. 2011;42:3105-3109.
29. Rim TH, Kim DW, Han JS, Chung EJ. Retinal vein occlusion and the risk of stroke development: a 9-year nationwide population-based study. *Ophthalmology*. 2015;122:1187-1194.
30. Arntz RM, van den Broek SM, van Uden IW, et al. Accelerated development of cerebral small vessel disease in young stroke patients. *Neurology*. 2016;87:1212-1219.
31. Ostergaard L, Engedal TS, Moreton F, et al. Cerebral small vessel disease: capillary pathways to stroke and cognitive decline. *J Cereb Blood Flow Metab*. 2016;36:302-325.
32. Kim BJ, Lee SH. Prognostic impact of cerebral small vessel disease on stroke outcome. *J Stroke*. 2015;17:101-110.
33. Wong TY, Mitchell P. The eye in hypertension. *Lancet*. 2007;369:425-435.
34. Hayreh SS, Zimmerman MB. Fundus changes in branch retinal arteriolar occlusion. *Retina*. 2015;35:2060-2066.
35. Cai Z, Wang C, He W, et al. Cerebral small vessel disease and Alzheimer's disease. *Clin Interv Aging*. 2015;10:1695-1704.
36. Hayreh SS, Fraterrigo L, Jonas J. Central retinal vein occlusion associated with cilioretinal artery occlusion. *Retina*. 2008;28:581-594.
37. Kwon HM, Lynn MJ, Turan TN, et al. Frequency, risk factors, and outcome of coexistent small vessel disease and intracranial arterial stenosis: results from the Stenting and Aggressive Medical Management for Preventing Recurrent Stroke in Intracranial Stenosis (SAMMPRIS) Trial. *JAMA Neurol*. 2016;73:36-42.