

Following the Status of Visual Cortex Over Time in Patients With Macular Degeneration Reveals Atrophy of Visually Deprived Brain Regions

Rachel L. W. Hanson,^{1,2} Richard P. Gale,^{3,4} André D. Gouws,² Archana Airoyd,⁴ Martin T. W. Scott,¹ Farah Akthar,¹ Sophie Waterson,¹ Mason T. Wells,¹ Aaron J. Wright,¹ Kerry Bell,¹ Edward Silson,¹ Heidi A. Baseler,^{1,2,5} and Antony B. Morland^{1,2}

¹Department of Psychology, University of York, York, United Kingdom

²York Neuroimaging Centre, University of York, York, United Kingdom

³Department of Health Sciences, University of York, York, United Kingdom

⁴Academic Unit of Ophthalmology, York Teaching Hospitals NHS Foundation Trust, York, United Kingdom

⁵Hull York Medical School, University of York, York, United Kingdom

Correspondence: Antony B. Morland, Department of Psychology, University of York, York YO10 5DD, UK;
antony.morland@york.ac.uk.

Submitted: October 4, 2018

Accepted: October 4, 2019

Citation: Hanson RLW, Gale RP, Gouws AD, et al. Following the status of visual cortex over time in patients with macular degeneration reveals atrophy of visually deprived brain regions. *Invest Ophthalmol Vis Sci*. 2019;60:5045–5051. <https://doi.org/10.1167/iovs.18-25823>

PURPOSE. Previous research has shown atrophy of visual cortex can occur in retinotopic representations of retinal lesions resulting from eye disease. However, the time course of atrophy cannot be established from these cross-sectional studies, which included patients with longstanding disease of varying severity. Our aim, therefore, was to measure visual cortical structure over time in participants after onset of unilateral visual loss resulting from AMD.

METHODS. Inclusion criteria were onset of acute unilateral neovascular AMD with bilateral dry AMD based on clinical examination. Therefore, substantial loss of unilateral visual input to cortex was relatively well-defined in time. Changes in cortical anatomy were assessed in the occipital lobe as a whole, and in cortical representations of the lesion and intact retina, the lesion and intact projection zones, respectively. Whole brain, T1-weighted magnetic resonance imaging was taken at diagnosis (before antiangiogenic treatment to stabilize the retina), during the 3- to 4-month initial treatment period, with a long-term follow-up approximately 5 (range 3.8–6.1 years) years later.

RESULTS. Significant cortical atrophy was detected at long-term follow-up only, with a reduction in mean cortical volume across the whole occipital lobe. Importantly, this reduction was explained by cortical thinning of the lesion projection zone, which suggests additional changes to those associated with normal aging. Over the period of study, antiangiogenic treatment stabilized visual acuity and central retinal thickness, suggesting that the atrophy detected was most likely governed by long-term decreased visual input.

CONCLUSIONS. Our results indicate that consequences of eye disease on visual cortex are atrophic and retinotopic. Our work also raises the potential to follow the status of visual cortex in individuals over time to inform on how best to treat patients, particularly with restorative techniques.

Keywords: magnetic resonance imaging, age-related macular degeneration, visual cortex, cortical thinning

It has recently emerged that eye disease can result in secondary structural changes within primary visual cortex. This is true whether the eye disease is congenital, for example in ocular albinism,¹ or acquired, for example in AMD.² Most commonly, atrophy demonstrated by a reduction in cortical thickness or volume is reported in the retinotopic representation of the lesions that are a consequence of the disease.^{1–8} Conversely, some studies have reported atrophy in retinotopic representations of intact but not lesioned retina in monocularly blind⁹ and AMD patients,⁷ whereas others revealed significant thickening of cortical representations of the intact retina, believed to be a compensatory phenomenon.¹⁰ Controversy, therefore, remains over the exact nature of the response of

visual cortex to retinal disease and furthermore the timing of such changes.

AMD is an excellent model to study the consequences of vision deprivation, as it leads to a loss of retinal input to the cortical representation of the central visual field. However, the most common form of the disease progresses slowly, and onset of visual loss is a challenge to pinpoint in time. However, the neovascular (nvAMD) form of the disease, characterized by fluid leakage and hemorrhage in the central macula, has an acute onset, therefore visual loss is well-defined.¹¹ nvAMD generally manifests unilaterally, with disease onset in the second eye occurring in 50% of patients within 3 years after unilateral loss.¹²



TABLE. Participant Demographics

Participant	Sex	Treated Eye	Age, y		MRI Visit	
			Baseline	Long-Term Assessment	Short-Term Assessment, mo	Long-Term Assessment, y
P3	Male	Right	67.11	73.10	3	6.01
P5	Female	Right	75.01	79.09	3	4.08
P6	Male	Right	81.05	86.01	4	4.08
P7	Male	Right	71.04	75.09	3	4.05
P8	Female	Right	70.00	73.10	4	3.10
P9	Female	Right	70.07	74.03	4	4.10
P10	Male	Left	79.00	82.08	3	3.08

To assess the time course of structural changes to visual cortex resulting from a loss of input, we recruited individuals recently diagnosed with onset of acute unilateral nvAMD who had established bilateral retinal disease. As a result, a significant unilateral change of input to visual cortex was well-defined in time.

NvAMD affects 40,000 new people in the United Kingdom every year,¹³ and when left untreated, leads to severe sight impairment. Current treatment involves regular intraocular anti-VEGF injections that restore approximately half the initially lost visual acuity^{14–16} by halting leakage, therefore decreasing central retinal thickness.^{16–18} Following an initial improvement of visual acuity by month 3, a long-term slow decline in visual acuity can be observed.^{17,19,20} The patients we tested received standard treatment to preserve and stabilize vision.

This study aimed to observe the short- and long-term nature of visual cortical changes in the context of unilateral visual loss due to nvAMD. Previous studies focused on testing patients with established bilateral disease, between 1 and 42 years postonset.^{2–4,7,10} Therefore, our first objective was to determine whether cortical changes occurred over a short timescale of 3 months. The second objective, met by the opportunity to follow patients long-term, was to determine what changes occurred several years after the acute onset of unilateral nvAMD. The third objective was to establish whether cortical changes were atrophic and if they were specific to the cortical representation of the retinal lesion.

MATERIALS AND METHODS

Participants

Written informed consent was obtained from all participants. This study followed the tenets of the Declaration of Helsinki with approval granted by York Neuroimaging Centre Research, Ethics and Governance Committee and the NHS Research Ethics Committee (IRAS: 27966, 199112).

Ten participants were recruited from York Teaching Hospital NHS Foundation Trust. Inclusion criteria were onset of acute unilateral nvAMD with bilateral dry AMD based on clinical examination. Thus, a significant reduction in input to visual cortex from unilateral disease was well-defined in time. Recruitment took place between January 2011 and November 2013. Routine clinical treatment was administered in accordance with guidance from the National Institute of Health and Clinical Excellence.²¹

Initial assessments and magnetic resonance imaging (MRI) were carried out before commencing routine anti-VEGF treatment for nvAMD, with short-term assessments taking place a mean of 3.5 months (range, 3–4 months) later in all 10

participants. Long-term assessments were carried out a mean of 4.8 years (range, 3.8–6.1 years) after diagnosis in seven participants in this group, because two participants did not join the follow-up component of the study for long-term assessments and one died. Our analysis was therefore restricted to assessing those seven patients in whom we had measures at all time points. The mean age of participants at baseline was 73.5 years (range, 67.1–81.5 years), increasing to 77.9 years (range, 73.1–86.1 years) at follow-up (Table).

Design

In this longitudinal study, structural MRI was acquired at three intervals: a baseline assessment took place before participants received the first anti-VEGF treatment (month 0), a short-term assessment took place a mean of 3.5 months post-baseline, with a long-term assessment occurring a mean of 4.8 years post-baseline (Table). Routine clinical assessments, detailed below, coincided with the MRI visits.

Procedures

MRI. Structural MRI was acquired using an eight-channel phased-array head coil tuned to 127.4 MHz, on a GE Healthcare (Little Chalfont, UK) 3-Tesla Signa HD Excite scanner. One T1-weighted anatomical volume was acquired (repetition time, 8 ms; echo time, 3 ms; inversion time, 450 ms; voxel size, $1.13 \times 1.13 \times 1 \text{ mm}^3$; flip angle, 20° ; 256×256 matrix; field of view, 290 mm). All participants were instructed to lie as still as possible during the scan. Foam padding was used around the head to minimize movement, with earplugs provided to protect against scanner noise.

Analysis. Cortical reconstruction and volumetric segmentation were performed using the Freesurfer analysis suite (version 5.3, available at: <http://surfer.nmr.mgh.harvard.edu/>). This process includes removal of non-brain tissue, intensity normalization,²² tessellation of the gray/white matter boundary, automated topology correction^{23,24} surface deformation following intensity gradients to optimally place the gray/white matter and gray/cerebrospinal fluid boundaries at the location where the greatest shift in intensity defines the transition to the other tissue class.

Cortical anatomy was assessed in two ways with the following rationale. We first assessed gray matter volume of occipital cortex. This coarse measurement has the advantage of not being susceptible to individual differences in the cortical representations of the visual field while also capturing representations outside primary visual cortex. At the same time, however, analysis of the whole occipital cortex does not allow hypotheses concerning the retinotopic nature of cortical changes. We turned, therefore, to a more focused region of interest (ROI) analysis, gathering information explicitly testing

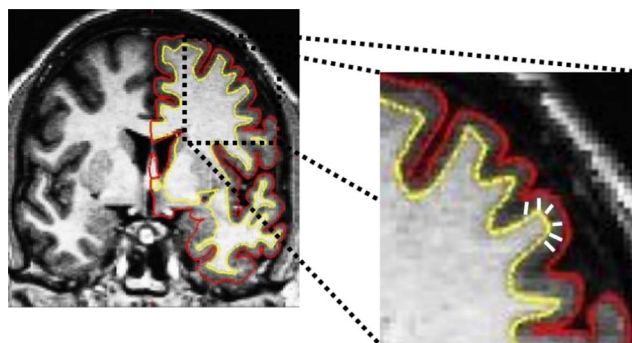


FIGURE 1. T1-weighted MRI image showing the boundary between the white and gray matter surface, referred to as the white surface (yellow line) and the gray matter and cerebrospinal fluid, referred to as the pial surface (red line). The distance between the white and pial surfaces gives the thickness at each location of cortex (white line).

regions of primary visual cortex representing lesioned and intact retina. The occipital pole and calcarine sulcus were selected, as they coincide with the lesion and intact projection zones for individuals with central visual loss. In defining such regions on the cortical surface, cortical thickness offers a sensible way to gauge the status of the visual representation that can be compared over time. Our target areas of the brain were defined using Freesurfer's Destrieux Atlas using the following parcellations: occipital cortex: 2, 11, 19, 20, 22, 42, 44, 51, 57, 58, 59, 65; lesion projection zone: 42; intact projection zone: 44.²⁵

Mean gray matter volume was extracted from each parcellation within the occipital cortex ROI, from both the left and right hemispheres. An average across hemispheres was then calculated for each participant, creating the final entire occipital cortex ROI. A paired-samples *t*-test assessed changes in cortical volume among the three intervals. Mean cortical thickness was extracted following this same procedure for the lesion and intact projection zones, calculated as the shortest distance between the gray/white matter boundary and the gray/cerebrospinal fluid boundary at each vertex across the cortex in millimeters, averaged over all vertices within each ROI (see Fig. 1). A paired-samples *t*-test assessed changes in cortical thickness within each ROI among the same three intervals.

Routine Clinical Assessments. Best-corrected visual acuity and central retinal thickness were acquired in all seven participants at all time points

Best-Corrected Visual Acuity. Standard clinical visual acuity was measured in an illuminated room at 4 m, with the participant's spectacle correction in each eye using an ETDRS (Early Treatment Diabetic Retinopathy Study) letter chart.²⁶ If participants were able to read four or more of the five letters on the first line of the chart they were asked to continue reading down the chart until they could read fewer than three letters on a single line. At this point, the total number of letters read correctly was recorded and an additional 30 letters were added to the total. If participants were unable to read four letters correctly on the first line, they were brought to 1 m and asked to continue reading down the chart until they could read fewer than three letters on a single line. Thirty letters were not added to the final ETDRS score in this circumstance.

Central Retinal Thickness. Effectiveness of anti-VEGF treatment in reducing the consequence of choroidal neovascularization over time can be measured using central retinal thickness. A reduction in central retinal thickness will indicate resolution of the edema due to treatment. This was measured using 1 mm³ subfield central retinal thickness with spectral-

domain optical coherence tomography (Cirrus OCT; Carl Zeiss Meditec, Dublin, CA, USA). A standard macular cube (128 × 256 × 518) assessment took place in an illuminated room, acquiring retinal images through dilated pupils for the treated and untreated eyes of each participant.

Analysis. Changes in best-corrected visual acuity and central retinal thickness were analyzed for the treated and untreated eyes at each session. As ETDRS letter scores and central retinal thickness values did not pass tests for normality (Shapiro-Wilk, $P < 0.001$), a Wilcoxon signed rank test assessed changes over time.

RESULTS

MRI

Our first and second objectives set out to determine whether cortical changes occurred within the initial treatment period following the onset of unilateral nvAMD (short-term) and what cortical changes occurred over time (long-term). Compared with baseline, we reveal no significant changes in cortical volume at the short-term assessment (31,580 mm³, $t[6] = 0.757$, $P = 0.478$); however, there is a significant reduction in cortical volume at long-term follow-up (31,767 mm³ versus 28,639 mm³, $t[6] = 3.033$, $P = 0.023$); indeed, six of the seven participants showed a reduction in volume. There was also a significant difference in cortical volume between the short-term and long-term assessments ($t[6] = 2.689$, $P = 0.036$) (Fig. 2B).

We next asked whether changes in volume were reflected by cortical atrophy: a thinning of cortex in identifiable retinotopic representations of the retinal lesion. The two regions we selected showed different results (Figs. 2C, 2D). In the intact projection zone, mean cortical thickness changed very little (Fig. 2C); neither short-term (1.81 mm, $t[6] = 1.218$, $P = 0.269$) nor long-term (1.76 mm, $t[6] = 1.021$, $P = 0.347$) assessments yielded significant differences compared with baseline (1.82 mm). There was also no significant difference between the short- or long-term assessments ($t[6] = 0.793$, $P = 0.458$). In contrast, the lesion projection zone was significantly thinner at the long-term (1.94 mm, $t[6] = 2.389$, $P = 0.027$, one-tailed), but not short-term (2.08 mm, $t[6] = 1.857$, $P = 0.113$) assessments compared with baseline (2.11 mm), with a significant difference between the short- and long-term assessments ($t[6] = 2.467$, $P = 0.025$). Although there is not a significant interaction between timepoint and ROI, these data are suggestive that cortical atrophy is a feature present at long-term follow-up and larger in the cortical representation of the lesioned retina.

While results indicate anatomical changes in visual areas of the brain are atrophic and retinotopic, we wanted to check whether age-dependent changes in the whole brain explained any effects detected. Cortical thinning associated with natural aging is well documented, although there is some discrepancy whether cortical thinning of primary visual cortex occurs with increasing age^{27,28} or not.^{29,30} Griffis et al.³¹ reported age-dependent cortical thinning specific to peripheral but not central representations of visual cortex. To investigate whether reductions in mean thickness observed in this study are not simply a consequence of natural aging, a linear regression analysis investigated changes to the lesion and intact projection zones in relation to changes to the whole brain. Excluding the occipital lobes, changes in the whole brain significantly accounted for 65% of the variance observed in the intact projection zone, ($F_{1,6} = 9.28$, $P = 0.029$) but only 31% of the variance in the lesion projection zone ($F_{1,6} = 2.32$, $P = 0.189$). Although there was no significant difference between the two

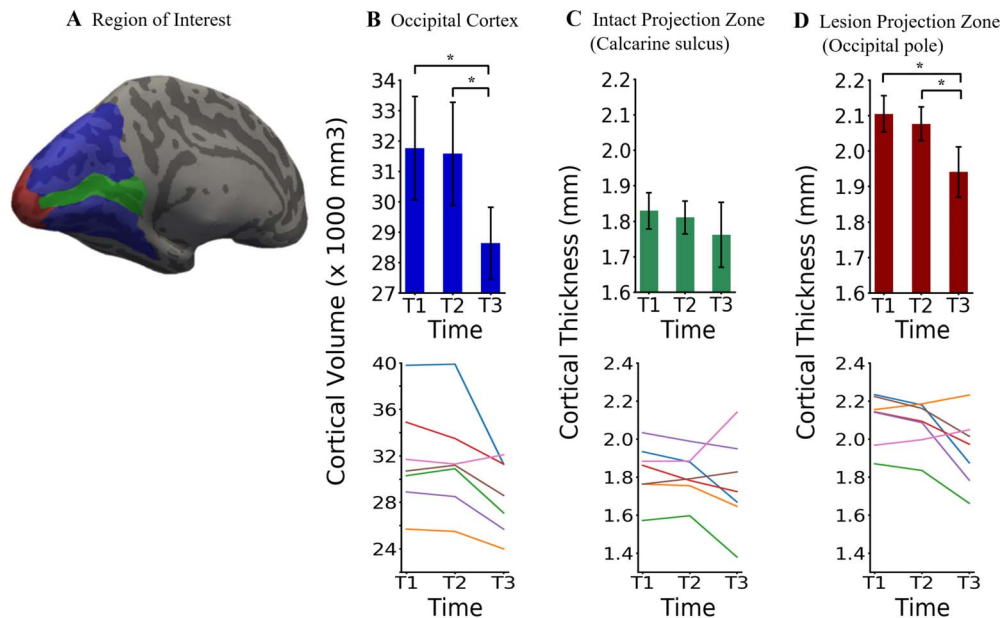


FIGURE 2. ROIs and their anatomical properties. (A) Surface reconstruction of a template brain with the occipital lobe (blue), lesion projection zone (red), and intact projection zone (green). Note that the latter two ROIs constitute elements of the larger occipital lobe ROI. (B) Volume of gray matter measured in the occipital lobe ROI at the three times of measurement. T1 refers to the baseline measure, T2 refers to the short-term assessment, and T3 refers to the long-term assessment. Also plotted is the cortical thickness of gray matter detected within the intact projection zone (C) and lesion projection zone (D) ROIs at three times of measurement. Line graphs for B–D represent individual changes in cortical structure for each participant at each time point. In B–D, statistically significant differences at $P < 0.05$ are indicated with an * and error bars represent ± 1 SEM.

ROIs, because the whole-brain effects accounted for more of the variance in the intact projection zone, the data are suggestive that the reductions in cortical thickness of the lesion projection zone are due to decreased retinal input rather than aging.

Disease Progression Over Time

What factors might determine the changes we observed in visual cortex? If the retinal lesions remain relatively stable over time, it is likely that cortical atrophy was a result of the duration of reduced input to cortex. However, if the retinal lesion progresses over time, we would be unable to dissociate the effects of disease progression and time on cortical atrophy. To monitor disease progression, measures of visual acuity and central retinal thickness were taken, coinciding with the MRI timepoints.

Visual acuity measures are shown in Figure 3A. Median acuity across the seven participants was below the normal range in both treated and untreated eyes due to longstanding vision loss associated with bilateral dry AMD. Short-term assessments show visual acuity increased in the treated eye compared with baseline but not significantly (T2 versus T1: $z = -1.690$, $P = 0.091$). At long-term follow-up, acuity was still improved relative to baseline, but again not significantly (T3 versus T1: $z = -0.676$, $P = 0.499$). A similar pattern of results was observed for the untreated eye, with no significant changes in acuity between baseline and short-term (T2 versus T1: $z = -1.951$, $P = 0.051$), or baseline and long-term follow-up (T3 versus T1: $z = -0.169$, $P = 0.866$). As can be seen in Figure 3C, a decrease in visual acuity is evident in the untreated eye for five of seven participants between the short- and long-term assessment (T2 versus T3). Although the changes are not significant, the gradual decline in visual acuity could indicate changes in cortical input over time.

We also tracked any changes in retinal anatomy with treatment by measuring central retinal thickness as an indicator of resolved edema (Fig. 3D). Compared with baseline, there was a significant decrease in central retinal thickness at the short-term assessment in the treated eye (T2 versus T1: $z = -2.366$, $P = 0.018$), which remained significant at long-term follow-up (T3 versus T1: $z = -2.366$, $P = 0.018$). For the untreated eye, although a decrease in central retinal thickness was observed in five of seven participants, this was not significant, either between baseline and short-term (T2 versus T1: $z = -0.254$, $P = 0.799$) or baseline and long-term follow-up (T3 versus T1: $z = -0.507$, $P = 0.612$) with data remaining within the normal range.

Taken together, measures of visual function and retinal anatomy appear to indicate that although vision was subnormal in both eyes, it was largely stable over the period of our study. This suggests that treatment was successful in halting disease progression in the treated eye with central retinal thickness indicating resolution of the edema. Nevertheless, a gradual decline in both eyes in some participants means we cannot assert that there is no change to the input to cortex over time.

DISCUSSION

This study shows, for the first time, the time course of structural changes to visual cortex following the onset of acute unilateral vision loss due to nvAMD. We report that atrophy (shrinkage) of visual cortex, detectable in a small number of individuals followed longitudinally, is also retinotopic as it was detected in the representation of the central visual field, that is, the macular lesion projection zone. Atrophy was not detected over the initial treatment period of 3 to 4 months but developed over several years.

Our findings reinforce the evidence for retinotopic and atrophic changes in the brain following eye disease.^{1–8}

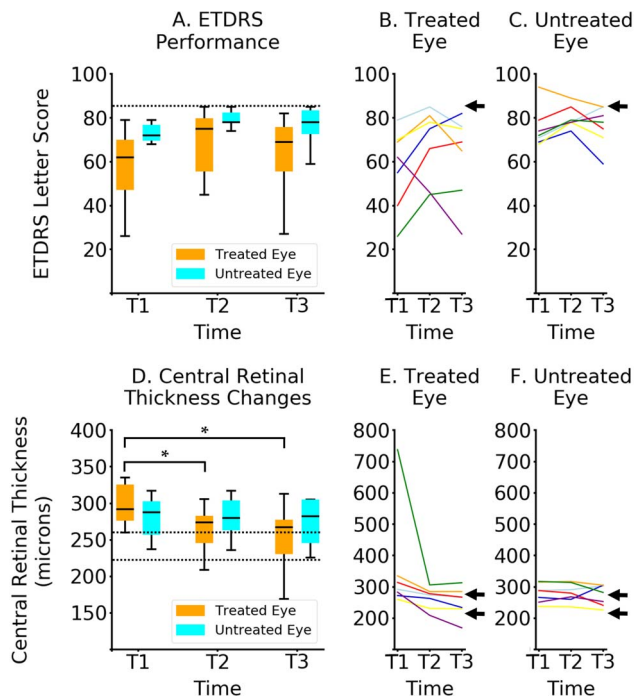


FIGURE 3. Clinical assessments. (A) Box plots showing visual acuity performance measured in ETDRS letter score for the treated eye (orange) and the untreated eye (cyan). Horizontal dashed line represents an ETDRS score of 84 letters, equivalent to 6/6 Snellen acuity, or 0.0 logMAR. (D) Box plots showing changes in central retinal thickness for the treated eye (orange) and the untreated eye (cyan). Horizontal dashed lines represent a healthy central retinal thickness range for the Cirrus SD-OCT machine.³² Horizontal lines represent the median, the upper and lower whiskers represent scores outside the middle 50%, whereas outliers are shown as points. Line graphs show individual changes in performance over time for each participant for the treated eye (B, E) and the untreated eye (C, F). Black arrows on plots B and C represent an ETDRS score of 84 letters, equivalent to 6/6 Snellen acuity, or 0.0 logMAR, whereas on plots E and F they represent a healthy central retinal thickness range for the Cirrus SD-OCT machine.³² All assessments were measured at three time points: T1 (baseline), T2 (short-term), and T3 (long-term assessment).

Converging evidence suggests that when retinal disease occurs, changes to visual cortex emerge in retinotopic representations of the retinal lesion. For example, albinism appears to result in changes at or near the occipital pole reflecting foveal hypoplasia,¹ and in an elegant study comparing individuals affected by glaucoma with peripheral field defects and macular degeneration with central visual defects, cortex was affected in regions corresponding to the representations of the affected visual fields.² Further research in central visual field defects arising from juvenile- and AMD also reveal atrophic changes in visual cortex and underlying white matter.³ The former appeared most pronounced in posterior visual cortical locations consistent with a retinotopic locus for the effect. However, these studies use cohorts of patients with bilateral vision loss. We find that even with significant unilateral loss, volume of the occipital cortex is reduced with a specific decrease in mean cortical thickness in the retinotopic representation of the retinal lesion.

In contrast to most studies reporting cortical loss following retinal disease, one study has reported significant thickening of retinotopic representations of the intact retina, which was attributed to potential compensatory mechanisms.¹⁰ As with many other studies, the patients had bilateral vision loss, thereby increasing the need for compensatory mechanisms.

However, the participants reported in this current study had predominantly unilateral vision loss, limiting the need for a compensatory mechanism, consistent with the lack of a significant change in representations of intact retina.

Our results also provide evidence for key elements that have not been addressed by previous investigations. Former studies have been cross-sectional, so although accumulating evidence of cortical loss has been relatively strong, there remained the possibility that cohorts of patients with visual deficits also may have comorbid brain properties differentiating them from control cohorts. Our longitudinal study demonstrates that atrophic changes can be observed within a group of patients followed over time.

We first asked whether changes occurred over a period of 3 to 4 months, which we believe is shorter than that previously assessed. We detected no change at this early stage, offering some reassurance that changes in the status of visual cortex detectable with MRI are not rapid. Most cross-sectional studies tested patients who had established visual loss between 1 and 42 years' duration.^{2-4,7,10} It would appear, therefore, that atrophic changes in visual cortex due to retinal disease may emerge between 3 and 12 months after disease onset. Future longitudinal studies would benefit from assessing the anatomy of visual cortex during the first 24 months after visual loss to characterize better the time course of brain changes. Our long-term follow-up successfully detected retinotopic atrophy, which has featured in the literature. However, the fact that such changes were detectable in such a small sample indicates that following individual patients over time may be a valuable way of assessing the status of visual cortex after vision loss.

As mentioned above, previous literature has primarily addressed cortical changes following bilateral retinal loss. However, some studies have found structural changes following unilateral loss. Previous studies have reported that monocular enucleation performed early in development results in shrinkage of ocular dominance columns³³⁻³⁵ and reduced white matter connections.³⁶ Moreover, early unilateral functional loss due to amblyopia has also been shown to result in structural changes to primary visual cortex.³⁷ Taken together, these studies suggest that changes to visual cortex can occur as a result of both anatomical and functional unilateral loss occurring early in development. Importantly, we demonstrate that cortical changes can follow unilateral loss of input in adulthood when the visual system has reached maturity.

Finally, routine clinical assessments highlighted the effectiveness of anti-VEGF treatment for nvAMD. In all but one participant, vision was subnormal in both eyes but remained relatively stable over time, consistent with previous literature studying larger cohorts.¹⁶⁻¹⁸ Although visual acuity and central retinal thickness did not indicate significant changes in both eyes over time, we cannot rule out entirely the possible contribution of disease progression in either or both eye to the cortical atrophy we observe.

Significant thinning of visual cortex may ultimately limit the success of restorative treatments for eye disease. At present, such treatments are limited by the quality of information generated at the retina,^{38,39} or indeed fed to the cortex directly.^{40,41} However, as the quality of visual information increases, the reliance on functional properties of visual cortex will come into play. For example, it has been proposed that cortical plasticity would be required to process the limited visual inputs that can be restored.³⁸ However, it is not known whether atrophy can be reversed, or whether sufficient cortical plasticity can be achieved once functional input is restored.

Our current results cannot inform whether atrophy reflects degenerative processes in the cortex. Anterograde transsynaptic degeneration has been reported within visual cortex in

patients following retinal disease/damage (for a review, see Ref. 42). Retrograde transsynaptic degeneration has also been observed; when cortex is lesioned, retinal ganglion cell numbers reduce in regions projecting to the lesioned part of cortex.^{43–47} It may be valuable therefore to probe visual cortex for measures that can track degeneration, perhaps using magnetic resonance spectroscopy to assess neurochemical signatures of necrosis or apoptosis.

We conclude that longstanding unilateral loss of input to visual cortex results in significant atrophy. However, there is a window, at least within 3 to 4 months after diagnosis, during which no detectable atrophy was present. This finding indicates that detrimental changes in visual cortex emerge relatively slowly.

Acknowledgments

The authors acknowledge with thanks the ESRC +3 White Rose Doctoral Training Centre scholarship (ES/J500215/1), the Fight For Sight project grant (1523/1524), the Wellcome Trust for its Institutional Strategic Support Fund awarded to the University of York and the Medical Research Council (G0401339), along with the ophthalmology research team at York Teaching Hospital NHS Foundation Trust.

Disclosure: **R.L.W. Hanson**, None; **R.P. Gale**, None; **A.D. Gouws**, None; **A. Airoyd**, None; **M.T.W. Scott**, None; **F. Akthar**, None; **S. Waterson**, None; **M.T. Wells**, None; **A.J. Wright**, None; **K. Bell**, None; **E. Silson**, None; **H.A. Baseler**, None; **A.B. Morland**, None

References

- Von Dem Hagen EAH, Houston GC, Hoffmann MB, Jeffery G, Morland AB. Retinal abnormalities in human albinism translate into a reduction of grey matter in the occipital cortex. *Eur J Neurosci*. 2005;22:2475–2480.
- Boucard CC, Hernowo AT, Maguire RP, et al. Changes in cortical grey matter density associated with long-standing retinal visual field defects. *Brain*. 2009;132:1898–1906.
- Hernowo AT, Prins D, Baseler HA, et al. Morphometric analyses of the visual pathways in macular degeneration. *Cortex*. 2014;56:99–110.
- Malania M, Konra J, Jägle H, Werner JS, Greenlee MW. Compromised integrity of central visual pathways in patients with macular degeneration. *Invest Ophthalmol Vis Sci*. 2017;58:2939–2947.
- Plank T, Frolo J, Brandl-Rühle S, et al. Gray matter alterations in visual cortex of patients with loss of central vision due to hereditary retinal dystrophies. *Neuroimage*. 2011;56:1556–1565.
- Neveu MM, von dem Hagen E, Morland AB, Jeffery G. The fovea regulates symmetrical development of the visual cortex. *J Comp Neurol*. 2008;506:791–800.
- Prins D, Plank T, Baseler HA, et al. Surface-based analyses of anatomical properties of the visual cortex in macular degeneration. *PLoS One*. 2016;11:1–14.
- Aguirre GK, Datta R, Benson NC, et al. Patterns of individual variation in visual pathway structure and function in the sighted and blind. 2016;11:1–24.
- Prins D, Jansonius NM, Cornelissen FW. Loss of binocular vision in monocularly blind patients causes selective degeneration of the superior lateral occipital cortices. *Invest Ophthalmol Vis Sci*. 2017;58:1304–1313.
- Burge WK, Griffis JC, Nenert R, et al. Cortical thickness in human V1 associated with central vision loss. *Sci Rep*. 2016;6:23268.
- Lim LS, Mitchell P, Seddon JM, Holz FG, Wong TY. Age-related macular degeneration. *Lancet*. 2012;379:1728–1738.
- Lee AY, Lee CS, Butt T, et al. UK AMD EMR Users Group Report V: benefits of initiating ranibizumab therapy for neovascular AMD in eyes with vision better than 6/12. *Br J Ophthalmol*. 2015;99:1045–1050.
- National Institute for Health and Care Excellence. Age-Related Macular Degeneration: NICE Guideline (2018). Available at: <https://www.nice.org.uk/guidance/ng82/resources/agere-lated-macular-degeneration-pdf-1837691334853>. Accessed April 18, 2018.
- Rosenfeld PJ, Brown DM, Heier JS, et al. Ranibizumab for neovascular age-related macular degeneration. *N Engl J Med*. 2006;355:1419–1431.
- Brown DM, Kaiser PK, Michels M, et al. Ranibizumab versus verteporfin for neovascular age-related macular degeneration. *N Engl J Med*. 2006;355:1432–1444.
- Kim JH, Lee DW, Chang YS, Kim JW, Kim CG. Twelve-month outcomes of treatment using ranibizumab or aflibercept for neovascular age-related macular degeneration: a comparative study. *Graefes Arch Clin Exp Ophthalmol*. 2016;254:2101–2109.
- Airoyd A, Venugopal D, Allgar V, Gale RP. Clinical characteristics and outcomes after 5 years *pro re nata* treatment of neovascular age-related macular degeneration with ranibizumab. *Acta Ophthalmol*. 2015;93:e511–e512.
- Keane PA, Liakopoulos S, Chang KT, et al. Relationship between optical coherence tomography retinal parameters and visual acuity in neovascular age-related macular degeneration. *Ophthalmology*. 2008;115:2206–2214.
- Singer MA, Awh CC, Sadda S, et al. HORIZON: an open-label extension trial of ranibizumab for choroidal neovascularization secondary to age-related macular degeneration. *Ophthalmology*. 2012;119:1175–1183.
- Rofagha S, Bhisitkul RB, Boyer DS, Sadda SR, Zhang K. Seven-year outcomes in ranibizumab-treated patients in ANCHOR, MARINA, and HORIZON: a multicenter cohort study (SEVEN-UP). *Ophthalmology*. 2013;120:2292–2299.
- National Institute for Health and Care Excellence. Ranibizumab and pegaptanib for the treatment of age-related macular degeneration. 2008 (updated 2012). NICE technology appraisal guidance [TA155]. Available at: <http://www.nice.org.uk/guidance/TA155>. Accessed April 19, 2018.
- Sled JG, Zijdenbos AP, Evans AC. A nonparametric method for automatic correction of intensity nonuniformity in MRI data. *IEEE Trans Med Imaging*. 1998;17:87–97.
- Fischl B, Liu A, Dale AM. Automated manifold surgery: constructing geometrically accurate and topologically correct models of the human cerebral cortex. *IEEE Trans Med Imaging*. 2001;20:70–80.
- Ségonne F, Pacheco J, Fischl B. Geometrically accurate topology-correction of cortical surfaces using nonseparating loops. *IEEE Trans Med Imaging*. 2007;26:518–529.
- Destrieux C, Fischl B, Dale A, Halgren E. Automatic parcellation of human cortical gyri and sulci using standard anatomical nomenclature. *Neuroimage*. 2010;53:1–15.
- Early Treatment Diabetic Retinopathy Study Research Group. Photocoagulation for diabetic macular edema: early treatment diabetic retinopathy study report number 1 early treatment diabetic retinopathy study research group. *Arch Ophthalmol*. 1985;103:1796–1806.
- Fjell AM, Westlye LT, Amlien I, et al. High consistency of regional cortical thinning in aging across multiple samples. *Cereb Cortex*. 2009;19:2001–2012.
- McGinnis SM, Brickhouse M, Pascual B, Dickerson BC. Age-related changes in the thickness of cortical zones in humans. *Brain Topogr*. 2011;24:279–291.
- Lemaitre H, Goldman AL, Sambataro F, et al. Normal age-related brain morphometric changes: nonuniformity across

- cortical thickness, surface area and gray matter volume? *Neurobiol Aging*. 2012;33:1–15.
30. Thambisetty M, Wan J, Carass A, An Y, Prince JL, Resnick SM. Longitudinal changes in cortical thickness associated with normal aging. *Neuroimage*. 2010;52:1215–1223.
 31. Griffis JC, Burge WK, Visscher KM. Age-dependent cortical thinning of peripheral visual field representations in primary visual cortex. *Front Aging Neurosci*. 2016;8:1–7.
 32. Sabouri MR, Kazemnezhad E, Hafezi V. Assessment of macular thickness in healthy eyes using cirrus HD-OCT: a cross-sectional study. 2016;5:104–111.
 33. Kelly KR, McKetton L, Schneider KA, Gallie BL, Steeves JKE. Altered anterior visual system development following early monocular enucleation. *Neuroimage Clin*. 2013;4:72–81.
 34. Kelly KR, Desimone KD, Gallie BL, Steeves JKE. Increased cortical surface area and gyrification following long-term survival from early monocular enucleation. *Neuroimage Clin*. 2015;7:297–305.
 35. Adams DL, Sincich LC, Horton JC. Complete pattern of ocular dominance columns in human primary visual cortex. *J Neurosci*. 2007;27:10391–10403.
 36. Wong NA, Rafique SA, Kelly KR, Moro SS, Gallie BL, Steeves JKE. Altered white matter structure in the visual system following early monocular enucleation. *Hum Brain Mapp*. 2017;39:133–144.
 37. Mendola JD, Conner IP, Roy A, et al. Voxel-based analysis of MRI detects abnormal visual cortex in children and adults with amblyopia. *Hum Brain Mapp*. 2005;25:222–236.
 38. Fine I, Boynton GM. Pulse trains to percepts: the challenge of creating a perceptually intelligible world with sight recovery technologies. *Philos Trans R Soc Lond B Biol Sci*. 2015;370:20140208.
 39. Fine I, Cepko CL, Landy MS. Vision research special issue: Sight restoration: prosthetics, optogenetics and gene therapy. *Vision Res*. 2015;111:115–123.
 40. Dobelle WH, Quest DO, Antunes JL, Roberts TS, Girvin JP. Artificial vision for the blind by electrical stimulation of the visual cortex. *Neurosurgery*. 1999;5:521–527.
 41. Pezaris JS, Reid RC. Demonstration of artificial visual percepts generated through thalamic microstimulation. *Proc Natl Acad Sci U S A*. 2007;104:7670–7675.
 42. Dinkin M. Trans-synaptic retrograde degeneration in the human visual system: slow, silent, and real. *Curr Neurol Neurosci Rep*. 2017;17:16.
 43. Beatty R, Sadun A, Smith L, Vonsattel J, Richardson E. Direct demonstration of transsynaptic degeneration in the human visual system: a comparison of retrograde and anterograde changes. *J Neurol Neurosurg Psychiatry*. 1982;45:143–146.
 44. Mitchell JR, Oliveira C, Tsiouris AJ, Dinkin MJ. Corresponding ganglion cell atrophy in patients with postgeniculate homonymous visual field loss. *J Neuroophthalmol*. 2015;35:353–359.
 45. Keller J, Sánchez-Dalmau BF, Villoslada P. Lesions in the posterior visual pathway promote trans-synaptic degeneration of retinal ganglion cells. *PLoS One*. 2014;9:97444.
 46. Jindahra P, Petrie A, Plant GT. Retrograde trans-synaptic retinal ganglion cell loss identified by optical coherence tomography. *Brain*. 2009;132:628–634.
 47. Yamashita T, Miki A, Goto K, et al. Retinal ganglion cell atrophy in homonymous hemianopia due to acquired occipital lesions observed using cirrus high-definition-OCT. *J Ophthbalmol*. 2016;2016:9.