

Posterior Vitreous Detachment in Normal Healthy Subjects Younger Than Age Twenty

Ayumi Hayashi,¹ Yoko Ito,¹ Yuki Takatsudo,¹ Naoto Hara,¹ Peter L. Gehlbach,² and Keisuke Mori¹

¹Department of Ophthalmology, International University of Health and Welfare, Nasushiobara-shi, Tochigi, Japan

²Wilmer Eye Institute, Johns Hopkins University School of Medicine, Baltimore, Maryland, United States

Correspondence: Keisuke Mori, Department of Ophthalmology, International University of Health and Welfare, 537-3 Iguchi, Nasushiobara-shi, Tochigi 329-2763, Japan; cfh.htra1.arms2@gmail.com, keisuke@iuhw.ac.jp.

Received: July 24, 2021

Accepted: September 27, 2021

Published: October 22, 2021

Citation: Hayashi A, Ito Y, Takatsudo Y, Hara N, Gehlbach PL, Mori K. Posterior vitreous detachment in normal healthy subjects younger than age twenty. *Invest Ophthalmol Vis Sci*. 2021;62(13):19. <https://doi.org/10.1167/iovs.62.13.19>

PURPOSE. To describe the initiation of posterior vitreous detachment (PVD) in the eyes of normal individuals, under 20 years of age, using wide-angle optical coherence tomography (OCT).

METHODS. This is an observational cross-sectional study. Montaged images of horizontal and vertical OCT scans were obtained in 63 healthy eyes of 35 consecutive subjects ranging in age from 4 to 17 years.

RESULTS. Forty-five eyes (71.4%) had obvious PVD, defined as a contiguous line of posterior cortical vitreous separated from the surface of the retina. Eighteen eyes (28.6%) had no PVD. The mean age of the individuals without PVD was significantly younger than those with PVD ($P = 0.008$). The spatial distribution of PVD initiation was highest in the superior quadrants, with the nasal, inferior, septum papillomaculæ, and temporal quadrants following in descending order of frequency ($P < 0.001$). PVD was observed to begin anterior to the premacular liquefied lacuna, where the vitreous gel directly adheres to the vitreoretinal interface. In the majority of subjects (80.6%), PVD was initiated anterior to the vascular arcades.

CONCLUSIONS. PVD can be observed by OCT to begin in the first and second decade of life. It begins in the mid-peripheral vitreous, most frequently in the superior quadrants anterior to the vascular arcades. In this study, all PVDs originated outside of the macular liquefied lacunae, where the vitreous gel adheres directly to the retina.

Keywords: posterior vitreous detachment, juvenile, optical coherence tomography, wide-angle

Posterior vitreous detachment (PVD) is one of the most important age-related events in the human eye. A separation of the posterior cortical vitreous from the internal limiting membrane of the retina is the fundamental change. PVD is considered complete when separation of the vitreous from the retina occurs in all areas posterior to the vitreous base.¹ PVD is now believed to be a progressive process occurring throughout life and usually completes without pathological sequelae.^{2–7} Despite this, PVD can still contribute to the development of prevalent vitreoretinal disorders, such as macular hole, macular pucker, vitreoretinal traction syndrome, retinal tears, retinal detachments, and vitreous hemorrhages, among others, if the process occurs pathologically.^{8–15} Therefore, a greater understanding of the physiological course of PVD remains important and may contribute to a greater understanding of these important diseases.

Historically, PVD has been studied in autopsy eyes without ocular disorders. In recent studies using ultrasonography and optical coherence tomography (OCT), it has been suggested that PVD begins in the macular region during middle age as a result of progressive vitreous liquefaction.^{2–6,14} Although OCT is capable of high-resolution

images of the vitreoretinal interface, standard OCT imaging protocols capture only the macular region, within a 9- to 12-mm radius, and thus may miss changes occurring in the mid-peripheral and peripheral fundus. To overcome this limitation, we have developed a wide-angle OCT imaging method that enables observation of the vitreoretinal interface from the macula to approximately the equator.^{16–18} The feasibility of this montage imaging technique has now been replicated by other study groups.^{19–21} Utilizing this method, we have reported that PVD changes are detectable predominantly in the midperipheral and peripheral regions in more than 90% of eyes in the third decade of life.⁷

In the same report, for subjects older than 20 years old, PVD was classified into the following five stages: stage 0, no PVD present; stage 1, peripheral PVD limited from paramacular to peripheral zone; stage 2, perifoveal PVD expanding to the periphery; stage 3, peripapillary PVD with persistent vitreopapillary adhesion alone; and stage 4, complete PVD. Stage 1 was subdivided into two categories: stage 1a, peripheral PVD with multilayered linear hyperreflective lines or interposed reflective material between retina and vitreous; and stage 1b, peripheral PVD without interposed material between retina and vitreous.⁷ Because most subjects in the



third decade already had associated changes with obvious PVD in the peripheral vitreous, the question was raised as to when, where, and how PVD is initiated. In this study, therefore, we further investigated the very early manifestations of PVD and its evolution by applying wide-angle OCT imaging to healthy eyes in young adults under 20 years of age.

METHODS

Subjects and Study Design

This was an observational cross-sectional study. A total of 63 eyes of 35 consecutive healthy normal volunteers younger than 20 years of age underwent wide-angle montage of OCT images of their entire viewable vitreoretinal interface at the International University of Health and Welfare between March 2018 and February 2019. The investigation adhered to all of the tenets of the Declaration of Helsinki. This study was approved by and conducted in compliance with the Ethics Committee of the International University of Health and Welfare (approval no. 13-B-225). Because the subjects were under 20 years of age, informed consent was obtained from the parents or guardians of the participants. The composition of the subject population was 20 female and 15 male participants, ranging in age from 4 to 17 years (mean \pm SD, 9.9 ± 3.2) (Table 1). All subjects were examined by indirect ophthalmoscopy, slit-lamp biomicroscopic examination, refraction, and best-corrected visual acuity testing. All volunteers had best-corrected visual acuity of 20/20 or better with refractive error from -3.0 to $+3.0$ diopter. Refraction was measured by an autorefractometer (RK-F2; Canon, Tokyo, Japan) with the use of cycloplegic eye drops (1% cyclopentolate hydrochloride or 1% atropine). Excluded were eyes with present or past vitreous, retina, or choroid diseases; trauma; abnormal intraocular pressure; history of systemic diseases relating to ocular disorders; or family history of genetic ocular diseases. Because it is sometimes difficult to obtain cooperation and high-quality images with young children, we used an image quality index, TopQ Image Quality, with swept-source OCT (DRI OCT Triton Plus; Topcon, Tokyo, Japan). Although a TopQ Image Quality of greater than 40 (full score, 100) is considered appropriate, subjects were excluded when the TopQ Image Quality was less than 95 to allow for the precise delineation of fine vitreous structure.

Wide-Angle Montage OCT Imaging

Standardized horizontal and vertical vitreoretinal sections through the fovea were collected with swept-source OCT and montaged in order to observe the wider vitreoretinal interface, approximately to the equator. All scans were

focused on the posterior cortical vitreous. The maximum imaging depth into the vitreous and vitreoretinal interface was obtained by positioning the retinochoroidal layers at the bottom of the image.²² To visualize clear vitreous images, we applied a planimetric image-editing system to enhance the contrast of the vitreous for better vitreous visualization.^{23–25} To then examine the morphologic features of the entire posterior vitreous cortex and the vitreoretinal interface, wide-angle montage OCT images from the macula to the periphery (approximately to the equator) were obtained as previously described.^{16–18} Montaged images were assembled using picture-editing software (Photoshop 5.5; Adobe, San Jose, CA, USA).

The classification of PVD was made by two independent masked graders (AH, YI). The presence of PVD was defined as having an obvious contiguous line of posterior cortical vitreous separated from the surface of the retina. When there was a disagreement, a third and experienced reader (KM) made the final judgment. In our previous report, the location of PVD origin was spatially located primarily in the mid-peripheral and peripheral vitreous, anterior to the papillomacular vitreous liquefaction, where the vitreous gel is directly adherent to the posterior cortical vitreous and the retinal surface. To precisely describe the location of PVD initiation in juvenile individuals, the PVD was subdivided using the vascular arcade as a landmark on the vertical OCT image. Because horizontal OCT images do not include the arcade vessels, three eyes with PVD on the horizontal scan but not in the vertical section were excluded from this element of the evaluation.

Statistical Analysis

PVD occurrence for each quadrant was statistically analyzed using the χ^2 test. The effect of age for each PVD stage and longitudinal distribution of PVD was compared using an unpaired *t*-test. The results were considered statistically significant at $P < 0.05$. All analyses were performed using commercially available software (Bell Curve for Excel 2.14; Social Survey Research Information, Tokyo, Japan).

RESULTS

In this group of volunteers younger than 20 years of age, all 63 eyes were classified as stage 0 or stage 1a. Stage 0 was defined as without PVD, and stage 1a was defined as having an obvious contiguous line of posterior cortical vitreous separated from the surface of the retina in the peripheral region (anterior to the macular region), associated with interposed reflective material or multilayered hyperreflective lines between the retina and vitreous. Of the 63 eyes examined, 18 eyes had stage 0 PVD (28.6%; mean age,

TABLE 1. Demographic Features and PVD Stages

Demographic	PVD Stage 0	PVD Stage 1a	Total
Male/female, <i>n</i>	8/10	20/25	28/35
Age (yr), mean \pm SD (range)	8.2 ± 3.0 (4–14)	10.5 ± 2.9 (6–17)	9.8 ± 3.1 (4–17)
Decade, <i>n</i> (%) [*]			
First (0–9 yr)	13 (44.8)	16 (55.2)	29 (100)
Second (10–19 yr)	5 (14.7)	29 (85.3)	34 (100)
Total	18 (28.6)	45 (71.4)	63 (100)

^{*}Because some subjects had different stages between right and left eyes, some data are expressed as the number of eyes (% of entire group).

TABLE 2. Age, PVD Stages, and Incidence of OCT Findings

	Total Incidence, <i>n</i> (%)	Age (yr), Mean \pm SD (Range)	PVD Stage 0, <i>n</i> (%)	PVD Stage 1a, <i>n</i> (%)
Bursa premacularis/PPVP	52 (82.5)	10.0 \pm 3.1 (6–17)	13 (72.2)	39 (86.7)
Prevascular vitreous fissure	11 (17.5)	10.0 \pm 2.8 (6–15)	2 (11.1)	9 (20.0)
Perpendicular vitreous fiber insertion	11 (17.5)	10.7 \pm 2.5 (6–15)	1 (5.6)	10 (22.2)
Granular hyperreflections	49 (77.8)	9.5 \pm 3.0 (4–16)	17 (94.4)	32 (71.1)
Discontinuous vitreoschisis	5 (7.9)	8.5 \pm 2.2 (6–12)	2 (11.1)	3 (6.7)
Contiguous vitreoschisis	41 (65.1)	9.8 \pm 3.0 (6–17)	9 (50.0)	32 (71.1)

PPVP, posterior precortical vitreous pocket.

8.2 \pm 3.0 years; median, 7 years; range, 4–14 years), and 45 eyes had stage 1a PVD (71.4%; mean age, 10.5 \pm 2.9 years; median, 10 years; range, 6–17 years). Stage 1a PVD was present in 55.2% of eyes in the first decade and in 85.3% of eyes in the second decade (Table 1). The mean age of the individuals with stage 0 PVD was significantly younger than those with stage 1a PVD ($P = 0.008$, t -test).

Premacular liquefied lacuna (so-called bursa premacularis²⁶ or posterior precortical vitreous pocket²⁷) was demonstrated in 52 eyes examined (82.5%; mean age, 10.0 \pm 3.1 years; range, 6–17 years). A prevascular vitreous fissure along the vascular arcade was observed in 11 eyes (17.5%; mean age, 10.0 \pm 2.8 years; range, 6–15 years). Granular hyperreflection in the peripheral cortical vitreous was identified in 49 eyes (77.8%; mean age, 9.5 \pm 3.0 years; range, 6–17 years) (Table 2).

Stage 0

Among 63 healthy eyes in this group of juveniles, 18 eyes (28.6%) had no evidence of PVD in any of the four quadrants imaged (Fig. 1). Granular hyperreflections were demon-




FIGURE 1. Wide-angle montaged OCT images of horizontal (A) and vertical (B) vitreoretinal cross-sections in an eye of a 6-year-old girl with stage 0 PVD. A highly magnified image of an inset in A corresponds to C, and the image in B corresponds to D. There was no PVD in either the horizontal or vertical section, but the premacular liquefied lacuna was clearly delineated. Noted were granular hyperreflections in the posterior vitreous cortex (asterisks in C and D).

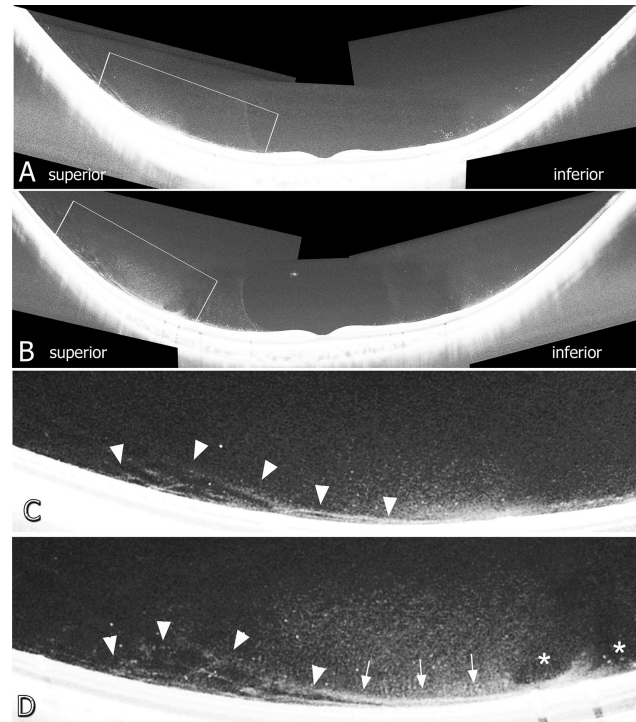


FIGURE 2. Wide-angle OCT images of vertical cross-sections of left (A) and right (B) eye of a 12-year-old girl with stage 0 PVD. A highly magnified image of an inset in A corresponds to C, and the image in B corresponds to D. Both eyes were in the process of progressing to stage 1a PVD. The confined and very narrow, but distinct, stratifications of the posterior vitreous cortex, defined as “discontinuous vitreoschisis,” were consistently distributed anterior to the vascular arcade (arrowheads in C). In the right eye (D), areas of discontinuous vitreoschisis (arrowheads) later connected with and became contiguous vitreoschisis (arrows). A prevascular vitreous fissure was also present (asterisk in D).

strated in 17 eyes (94.4%) with stage 0 PVD. Thirteen eyes (72.2%) had a premacular liquefied lacuna, and perpendicular vitreous fiber insertion was seen in one eye (5.6%) (Table 2). Discontinuous vitreoschisis was found in two eyes (11.1%), and nine eyes (50.0%) had contiguous vitreoschisis (Table 2, Fig. 2). Unlike contiguous vitreoschisis, there was a confined and very narrow, but distinct, stratification of the posterior vitreous cortex, conveniently defined as “discontinuous vitreoschisis,” which was distributed anterior to the vascular arcade.

Stage 1a

Among this group of juveniles, 45 eyes (71.4%) had stage 1a PVD. In 32 eyes (71.1%), granular hyperreflections were

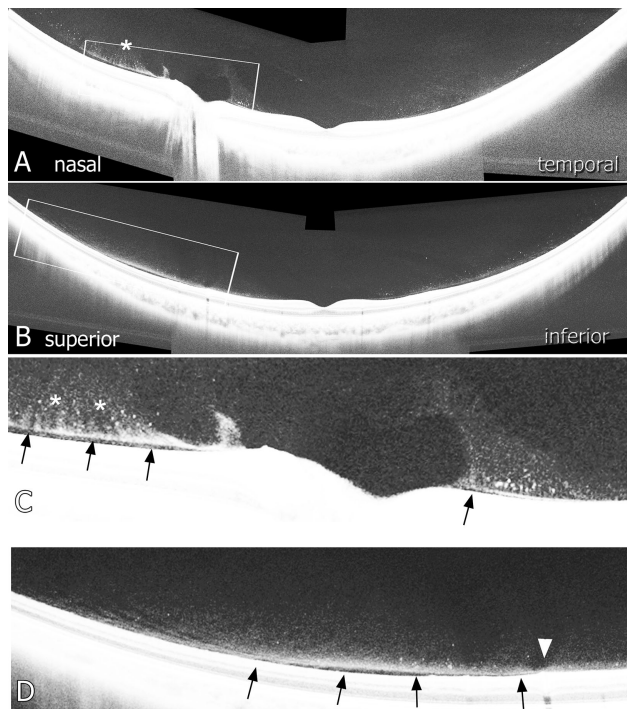


FIGURE 3. Wide-angle montaged images of horizontal (A) and vertical (B) vitreoretinal cross-sections in an eye of a 10-year-old boy with stage 1a PVD. A highly magnified image of an inset in A corresponds to C, and the image in B corresponds to D. Arrows indicate PVD lines in the nasal and superior quadrants and septum papillomaculae. Noted were granular hyperreflectivity and vitreous fibers connected to the posterior cortical vitreous perpendicularly (asterisks in A and C). PVD in the superior quadrant was located within the mid-periphery anterior to the arcade vessel (arrowhead in D).

associated with stage 1a PVD. Thirty-nine eyes (86.7%) had a premacular liquefied lacuna, prevascular vitreous fissure was present in nine eyes (20.0%), and perpendicular vitreous fiber insertion was present in 10 eyes (22.2%). Discontinuous

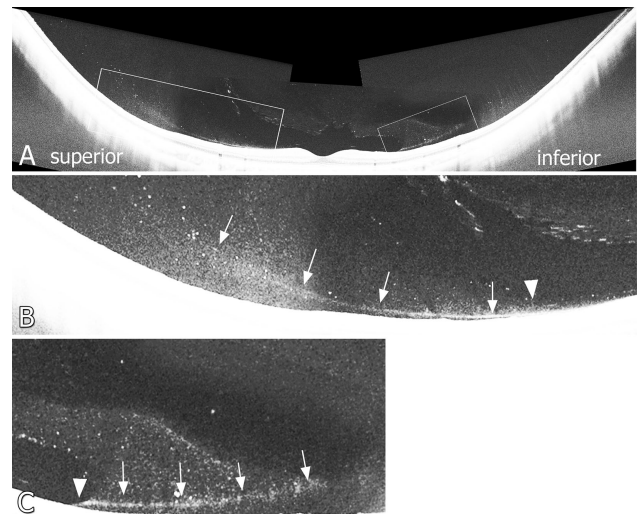


FIGURE 4. A wide-angle montaged image of vertical (A) vitreoretinal cross-sections in an eye of 14-year-old girl with stage 1a PVD. A highly magnified image of an inset in the superior quadrant corresponds to B and in the inferior quadrant to C. Arrows indicate contiguous lines of posterior cortical vitreous separated from the retinal surface in both superior and inferior quadrants. PVD expanded beyond the arcade vessels to the margin of the premacular liquefied lacuna (arrowheads).

vitreoschisis was found in three eyes (6.7%), and 32 eyes (71.1%) had contiguous vitreoschisis (Table 2; Figs. 3, 4). All stage 1a PVD originated in the mid-peripheral region anterior to the papillomacular vitreous liquefactions, where the vitreous gel directly adheres to the retina.

PVD Distribution

Stage 1a PVD was evident in the superior quadrant of 32 eyes (71.1%), in the nasal quadrant of 24 eyes (53.3%), in the inferior quadrant of 19 eyes (42.2%), in the temporal

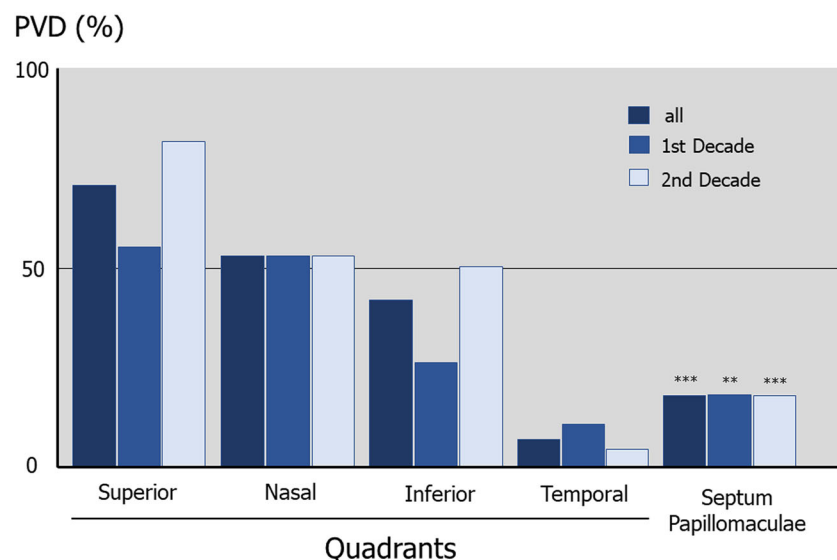


FIGURE 5. Geographic distribution of stage 1a PVD. There was a significant difference in the location of the PVD quadrant of origin. ** $P < 0.01$, *** $P < 0.001$.

quadrant of three eyes (6.7%), and in the septum papillomaculæ of eight eyes (17.8%). There was a significant difference in the location of the PVD quadrant of origin ($P < 0.001$, χ^2 test). Similar differences in the location of PVD origin were found to be significant in each decade (first decade, $P = 0.004$; second decade, $P < 0.001$) (Fig. 5).

Because the premacular liquefied lacuna is located posterior to the vascular arcade, eyes with stage 1a PVD were subdivided with regard to distribution using the vascular arcade as a landmark. Among 36 eyes with stage 1a PVD in the vertical OCT image, the PVD was located only anterior to the vascular arcade, without any expansion beyond the vascular arcade, in 29 eyes (80.6%; mean age, 10.5 ± 3.0 years). In the remaining seven eyes, the PVD was distributed across the vascular arcade but anterior to the premacular vitreous liquefaction (19.4%; mean age, 12.6 ± 2.3 years). No eye had a PVD that was only present posterior to the vascular arcade. The mean age of individuals with stage 1a PVD across the vascular arcade tended to be higher but was not significantly greater than for those with PVD located only anterior to the vascular arcade ($P = 0.08$, t -test).

DISCUSSION

Utilizing widefield OCT observations of the vitreoretinal interface in juveniles, we report several significant findings: (1) PVD changes were present in the majority of individuals under 20 years old (71%; 55% in the first decade and 85% in the second decade of life); (2) PVD began in the region anterior to the premacular liquefied lacuna, where the vitreous gel directly adheres to the vitreoretinal interface; and (3) in the majority of subjects, PVD was located only anterior to the vascular arcade without any posterior extension beyond the vascular arcade at this age. We also had occasion to capture images of discontinuous vitreoschisis, which is a very narrow and confined stratification of the posterior cortical vitreous. It has a morphological configuration distinct from that of contiguous vitreoschisis, which is commonly seen in the aged vitreous. We interpreted this finding as a very early anatomical change that precedes PVD. Finally, the location of initiation of PVD occurred in the following descending order of frequency: superior, nasal, inferior, septum papillomaculæ, and temporal quadrants in the age group of individuals less than 20 years old.

Historically, the timing of PVD has been believed to be an age-related but still acute event that occurs in much older eyes, often after the sixth decade.^{2,14,28} In recent years, conventional OCT imaging has provided more detailed information pertaining to the vitreoretinal interface; however, conventional imaging strategies provide images primarily of the macular area. In part due to these limitations, prior studies have concentrated on PVD development mainly in the posterior fundus and have continued to assume that PVD onset was a feature of the senescent vitreous.^{4,6} Accordingly, despite extensive literature describing a macular or perifoveal origin of PVD,¹⁻⁶ our prior⁷ and current work suggests that PVD is initiated primarily in the extramacular-peripheral vitreous, where conventional OCT imaging and imaging protocols have not visualized early changes.

We note here that in this study the origin of PVD was anterior to vitreous pockets or the area of Martegiani, where vitreous gel adheres directly to the retina. We also suggest that the impact of the tractional forces conveyed by vitreous movement during ocular saccades should significantly affect the development of PVD. Given that vitreous pockets

develop at around 3 years of age,²⁴ it is conceivable that tractional forces may evolve from the midperipheral fundus, outside of the vitreous pocket, as early as the first decade of life, facilitating early PVD progression. Based on prior evidence that PVD starts in the midperiphery and extends both posteriorly and anteriorly in adult eyes,⁷ and because macular liquefaction is usually located posterior to the vascular arcade, we searched for the early origins of PVD in young eyes by imaging posterior and anterior to the vascular arcade. The present study indicates that the majority of individuals examined in the juvenile group had PVD located only anterior to the vascular arcade. The mean age at which the PVD origin was limited to anterior to the vascular arcade tended to be younger than that at which PVD expansion posterior to the arcade occurred, suggesting that PVD initiation occurs anterior to the vascular arcade and progresses posteriorly toward the macula, in most cases.

During the course of this study, we did have occasion to capture a confined but distinct stratification of the posterior vitreous cortex located in the mid-periphery, anterior to the vascular arcade. This was a very early change in process of separation of the posterior vitreous cortex. Because the lamellar separation of the posterior cortical vitreous (as defined as “contiguous” vitreoschisis in the literature) is one of the early manifestations of posterior vitreous separation,⁷ this unique finding termed “discontinuous” vitreoschisis was not found in adults⁷ and is interpreted here as a very preliminary, precursor step to PVD that precedes the development of contiguous vitreoschisis. Although the incidence of contiguous vitreoschisis in our previous study⁷ with adults was approximately 40%, in this study that finding was greater than 65%. Vitreoschisis has been proposed to result from anomalous PVD, leaving the outer layer of the posterior vitreous cortex attached to the retina. This residual cortex is related to several vitreoretinal disorders.^{1,29-34} The present study demonstrates that vitreoschisis may be more universally associated with the phenomenon of initiation of physiological PVD than was previously appreciated.

Our present observations are limited by having only vertical and horizontal cross-sections; however, further evaluation with widefield two- or three-dimensional imaging may more quantitatively assess “discontinuous” and “contiguous” vitreoschisis in the future. At the present time, the observed phenomenon of discontinuous vitreoschisis is microscopic, on the order of several hundred micrometers. A further limitation of this study is the absence of longitudinal observations demonstrating the progression of PVD changes in individual patients over time. Currently, there are no publications demonstrating the longitudinal progression of PVD from the time of early initiation to completion.²⁻⁷ Longitudinal study of relevant aspects of the process of PVD is an ongoing project. We hope to confirm the stepwise progression of PVD from vitreoschisis initiation to completion.

When considering the course of PVD expansion across the entire plane of the fundus, stage 1a PVD was most frequently evident in the superior quadrant. This point of origin is consistent with prior reports.^{4,7} Pathophysiologically, the phenomenon may, at least in part, be due to gravitational forces that act on the superior vitreous body due to forces directed away from the retina in the upright position. Additionally, in this series of juvenile participants, prevascular vitreous fissures were evident in more than 17% of the group less than 20 years of age. This less dense, presumably liquid vitreous collection was discovered by Eisner^{35,36} and has been reported by several groups^{37,38} using cross-

sectional OCT, similar to that in the current report. Leong et al.³⁹ used en face OCT imaging to demonstrate that prevascular vitreous fissures are an almost universal feature of human eyes.

In conclusion, the present study indicates that the onset and limited spatial progression of PVD is evident in the first decade of life. It is most frequently initiated in the superior quadrant of the mid-peripheral fundus, mostly anterior to the vascular arcade. The youngest in this series to have stage 1a PVD was 6 years old. Tractional forces acting at the vitreoretinal interface are transmitted due, in part, to movement of the vitreous gel mass as a result of eye movements. Eye movement and further vitreous liquefaction over time serve to facilitate PVD.^{1,7} Tractional force transmission to the macular cortical vitreous may be in part damped by the macular liquefied structure. Vitreoschisis is a frequent phenomenon associated with PVD initiation, and micron-scale areas of “discontinuous” vitreoschisis may be among the earliest precursor observations visible on OCT that lead to development of PVD.

Acknowledgments

Supported in part by a grant-in-aid for scientific research from the Ministry of Education, Culture and Science in Japan (19K09998); by the Abbott Medical Optics (AMO) contract research grant program (AS2020A000025607); by a generous gift by Hiroyuki Isono, MD (KM); by Research to Prevent Blindness; and by gifts from the J. Willard and Alice S. Marriott Foundation, the Gale Trust, Herb Ehlers, Bill Wilbur, Rajandre Shaw, Helen Nassif, Mary Ellen Keck, Don and Maggie Feiner, Dick and Gretchen Nielsen, and Ronald Stiff (PLG).

Disclosure: **A. Hayashi**, None; **Y. Ito**, None; **Y. Takatsudo**, None; **N. Hara**, None; **P.L. Gehlbach**, None; **K. Mori**, Santen Pharmaceutical (F), Hoya (F), Novartis (F), Bayer (F), Senju Pharmaceutical (F), Nipro (P)

References

- Tozer K, Johnson MW, Sebag J. Vitreous aging and posterior vitreous detachment. In: Sebag J, ed. *The Vitreous in Health and Disease*. New York: Springer; 2014:131–150.
- Johnson MW. Posterior vitreous detachment: evolution and role in macular disease. *Retina*. 2012;32(suppl):S174–S178.
- Johnson MW. Perifoveal vitreous detachment and its macular complications. *Trans Am Ophthalmol Soc*. 2005;103:537–567.
- Uchino E, Uemura A, Ohba N. Initial stages of posterior vitreous detachment in healthy eyes of older persons evaluated by optical coherence tomography. *Arch Ophthalmol*. 2001;119(10):1475–1479.
- Johnson MW. Posterior vitreous detachment: evolution and complications of its early stages. *Am J Ophthalmol*. 2010;149(3):371–382.
- Itakura H, Kishi S. Evolution of vitreomacular detachment in healthy subjects. *JAMA Ophthalmol*. 2013;131(10):1348–1352.
- Tsukahara M, Mori K, Gehlbach PL, Mori K. Posterior vitreous detachment as observed by wide-angle OCT imaging. *Ophthalmology*. 2018;125(9):1372–1383.
- Gass JDM. Idiopathic senile macular hole. Its early stage and pathogenesis. *Arch Ophthalmol*. 1988;106(5):629–639.
- Gass JDM. Reappraisal of biomicroscopic classification of stages of development of a macular hole. *Am J Ophthalmol*. 1995;119(6):752–759.
- Duker JS, Kaiser PK, Binder S, et al. The International Vitreomacular Traction Study Group classification of vitreomacular adhesion, traction, and macular hole. *Ophthalmology*. 2013;120(12):2611–2619.
- Michels RG. A clinical and histopathologic study of epiretinal membranes affecting the macula and removed by vitreous surgery. *Trans Am Ophthalmol Soc*. 1982;80:580–656.
- Kishi S, Demaria C, Shimizu K. Vitreous cortex remnants at the fovea after spontaneous vitreous detachment. *Int Ophthalmol*. 1986;9(4):253–260.
- Gass JDM. *Stereoscopic Atlas of Macular Diseases: Diagnosis and Treatment*. 3rd ed. St. Louis, MO: Mosby; 1987:671–726.
- Wilkinson CP, Rice TA. *Michels Retinal Detachment*. 2nd ed. St. Louis, MO: Mosby; 1990:29–100.
- Novak MA, Welch RB. Complications of acute symptomatic posterior vitreous detachment. *Am J Ophthalmol*. 1984;97(3):308–314.
- Mori K, Kanno J, Gehlbach PL. Retinochoroidal morphology described by wide-field montage imaging of spectral domain optical coherence tomography. *Retina*. 2016;36(2):375–384.
- Mori K, Kanno J, Gehlbach PL. Montage images of spectral domain optical coherence tomography in eyes with idiopathic macular holes. *Ophthalmology*. 2012;119(12):2600–2608.
- Mori K, Gehlbach PL, Kishi S. Posterior vitreous mobility delineated by tracking of optical coherence tomography images in eyes with idiopathic macular holes. *Am J Ophthalmol*. 2015;159(6):1132–1141.
- Carrai P, Pichi F, Bonsignore F, et al. Wide-field spectral domain-optical coherence tomography in central serous chorioretinopathy. *Int Ophthalmol*. 2015;35(2):167–171.
- Pichi F, Carrai P, Bonsignore F, et al. Wide-field spectral domain optical coherence tomography. *Retina*. 2015;35(12):2584–2592.
- Choudhry N, Golding J, Manry MW, Rao RC. Ultra-widefield steering-based spectral-domain optical coherence tomography imaging of the retinal periphery. *Ophthalmology*. 2016;123(6):1368–1374.
- Pang CE, Freund KB, Engelbert M. Enhanced vitreous imaging technique with spectral-domain optical coherence tomography for evaluation of posterior vitreous detachment. *JAMA Ophthalmol*. 2014;132(9):1148–1150.
- Liu JJ, Witkin AJ, Adhi M, et al. Enhanced vitreous imaging in healthy eyes using swept source optical coherence tomography. *PLoS One*. 2014;9:e102950.
- Li D, Kishi S, Itakura H, et al. Posterior precortical vitreous pockets and connecting channels in children on swept-source optical coherence tomography. *Invest Ophthalmol Vis Sci*. 2014;55(4):2412–2416.
- Lavinsky F, Lavinsky D. Novel perspectives on swept source optical coherence tomography. *Int J Retina Vitreous*. 2016;2:25.
- Worst JG. Cisternal systems of the fully developed vitreous body in the young adult. *Trans Ophthalmol Soc UK*. 1977;97(4):550–554.
- Kishi S, Shimizu K. Posterior precortical vitreous pocket. *Arch Ophthalmol*. 1990;108(7):979–982.
- Pischel DK. Detachment of the vitreous as seen with slit-lamp examination. *Trans Am Ophthalmol Soc*. 1952;50:329–346.
- Sebag J, Niemeyer M, Koss MJ. Anomalous posterior vitreous detachment and vitreoschisis. In: Sebag J, ed. *The Vitreous in Health and Disease*. New York: Springer; 2014:241–263.
- Sebag J. Anomalous posterior vitreous detachment: a unifying concept in vitreoretinal diseases. *Graefes Arch Clin Exp Ophthalmol*. 2004;42(8):690–698.

31. Sebag J, Gupta P, Rosen R, et al. Macular holes and macular pucker: the role of vitreoschisis as imaged by optical coherence tomography/scanning laser ophthalmoscopy. *Trans Am Ophthalmol Soc.* 2007;105:121–131.
32. Sebag J. Vitreoschisis. *Graefes Arch Clin Exp Ophthalmol.* 2008;246:329–332.
33. Gupta P, Yee KMP, Garcia P, et al. Vitreoschisis in macular diseases. *Br J Ophthalmol.* 2011;95(3):376–380.
34. Sebag J. Vitreoschisis in diabetic macular edema. *Invest Ophthalmol Vis Sci.* 2011;52(11):8455–8456.
35. Eisner G. *Biomicroscopy of the Peripheral Fundus*. New York: Springer-Verlag; 1979.
36. Eisner G. Clinical anatomy of the vitreous. In: Jacobiec F, ed. *Ocular Anatomy, Embryology, and Teratology*. Philadelphia, PA: Harper & Row Publishers; 1982:391–424.
37. Pang CE, Schaal KB, Engelbert M. Association of prevascular vitreous fissures and cisterns with vitreous degeneration as assessed by swept source optical coherent tomography. *Retina.* 2015;35(9):1875–1882.
38. Uji A, Yoshimura N. Microarchitecture of the vitreous body: a high-resolution optical coherence tomography study. *Am J Ophthalmol.* 2011;168(8):24–30.
39. Leong BCS, Fragiotta S, Kaden TR, Freund KB, Zweifel S, Engelbert M. OCT en face analysis of the posterior vitreous reveals topographic relationships among premacular bursa, prevascular fissures, and cisterns. *Ophthalmol Retina.* 2020;4(1):84–89.